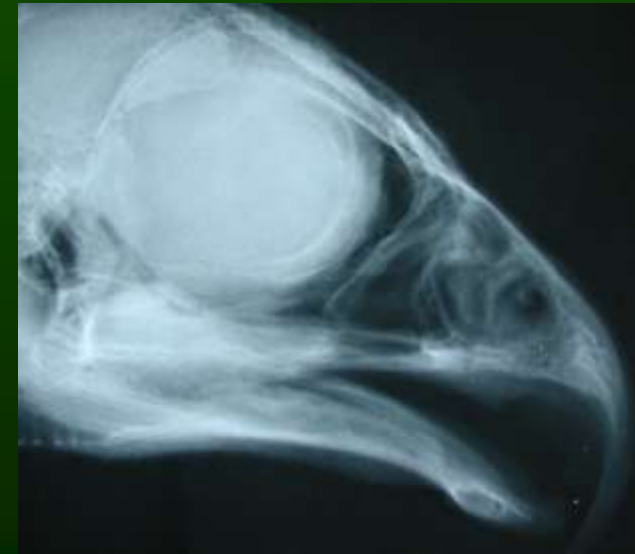



Injuries and diseases of falcons related to falconry utilization



MVDr. Ladislav Molnár, PhD

**Avian and Wild life Clinic
University of Veterinary Medicine
Slovakia**

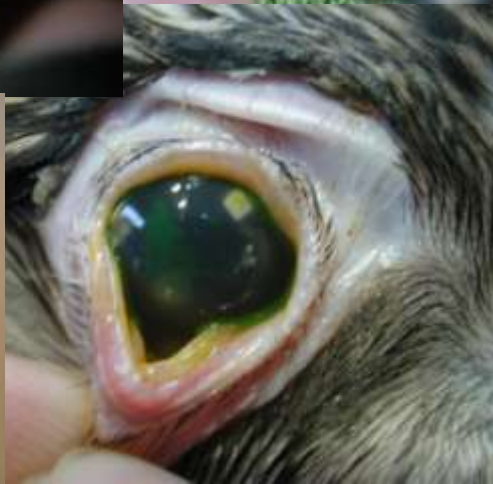

Falconry equipment and falcon health

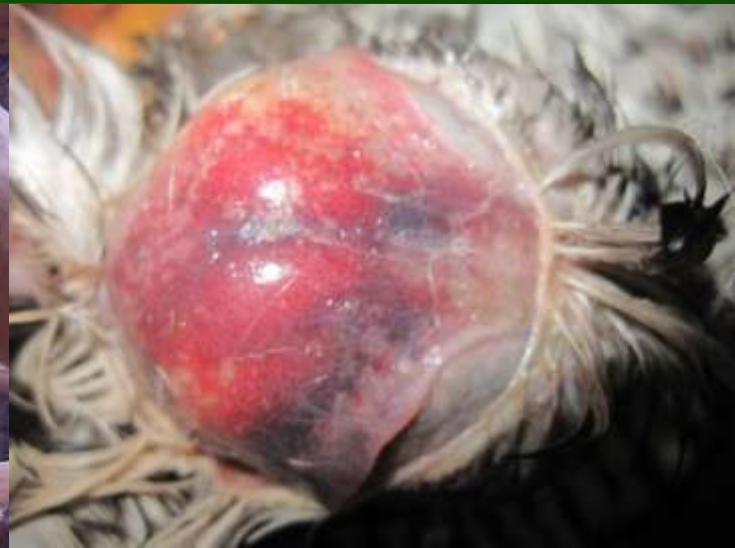



•Eye keratitis

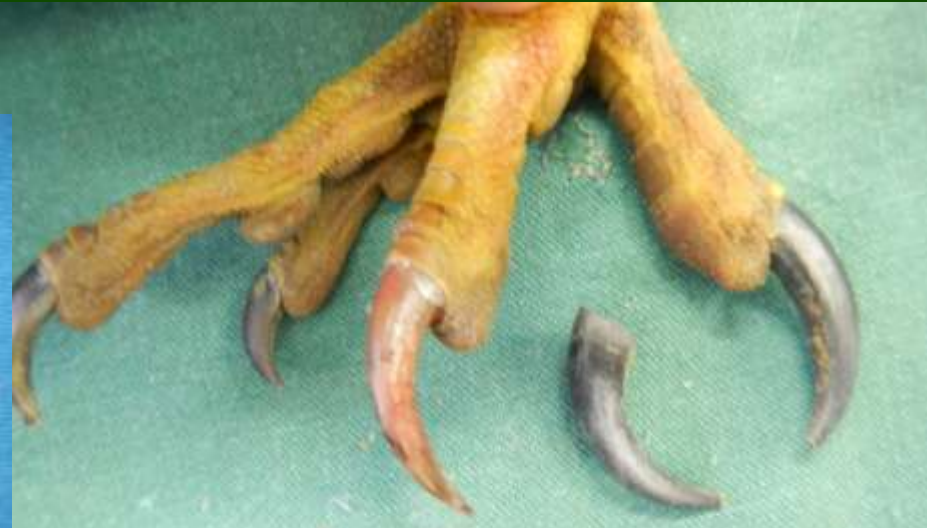
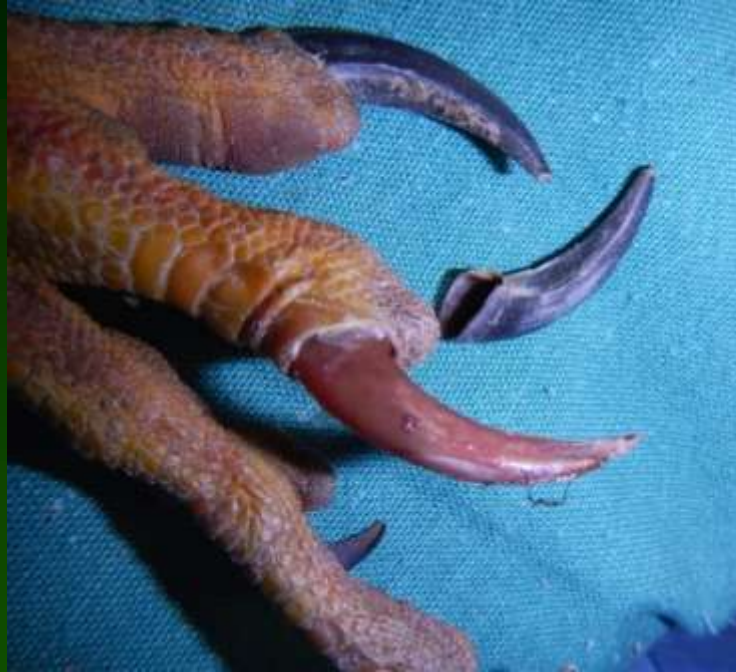
Subdural haemorrhages

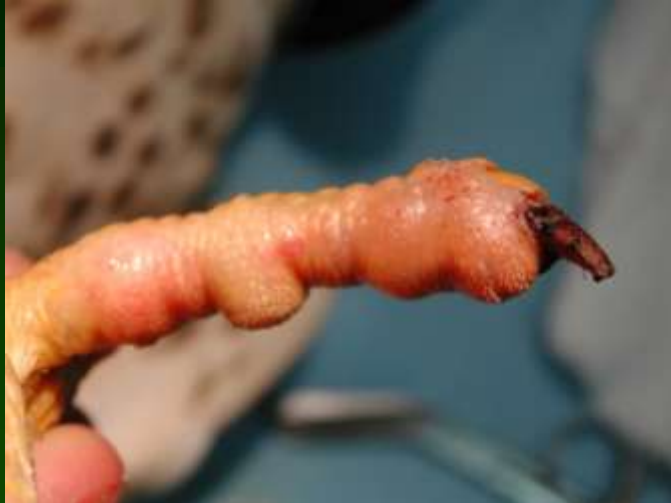



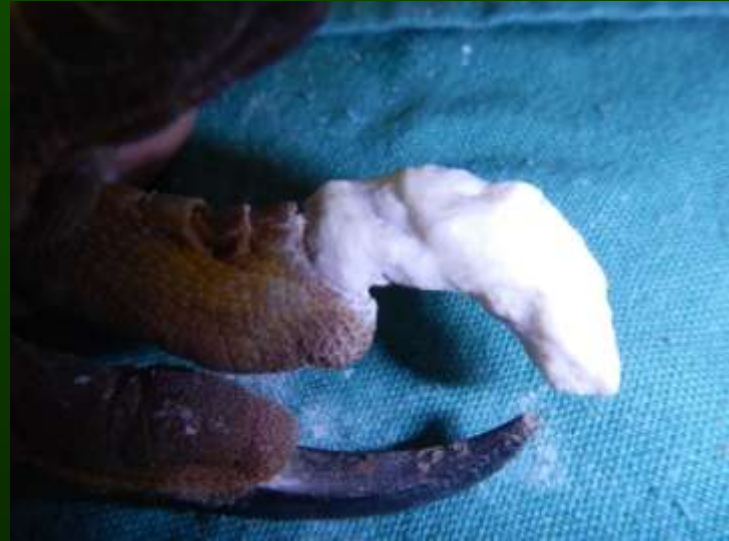Traumatic injuries of talons and beak.



Traumatic injuries of talons and beak

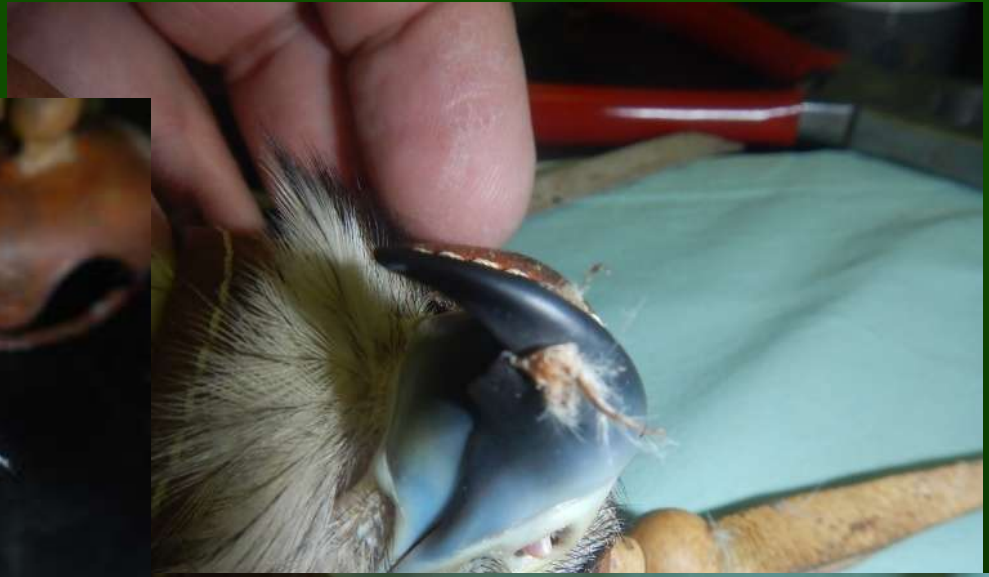

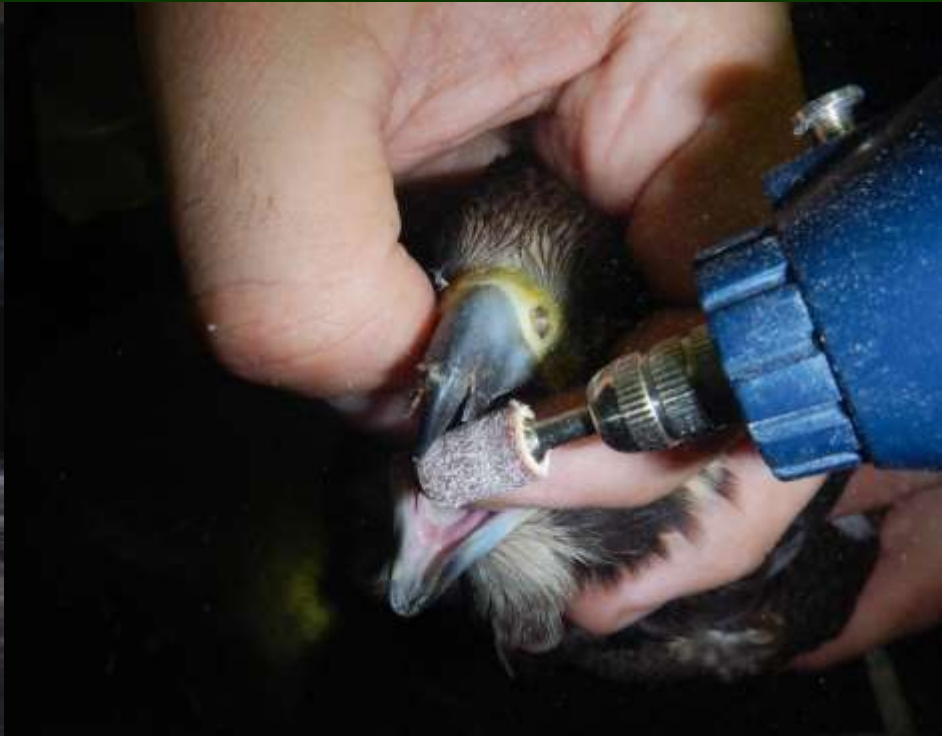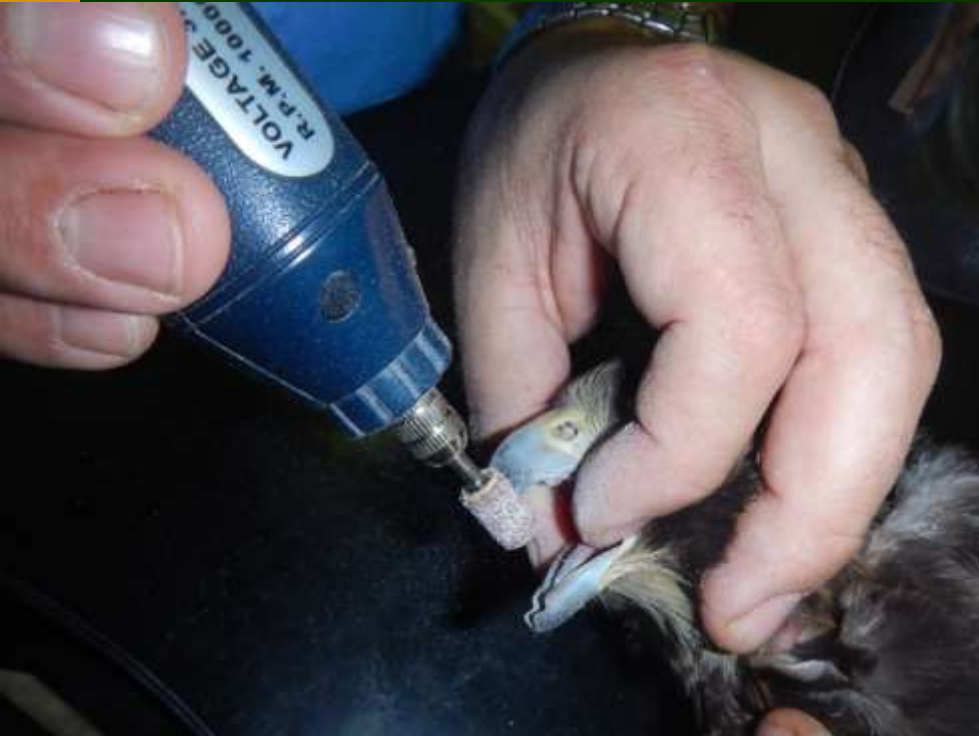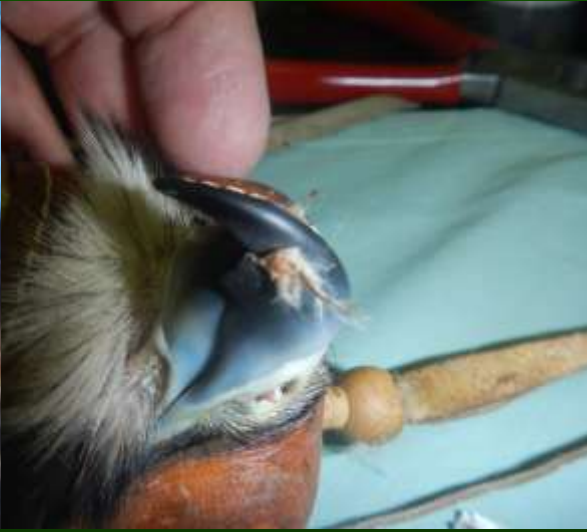Thermoplast or epoxy talon replacement



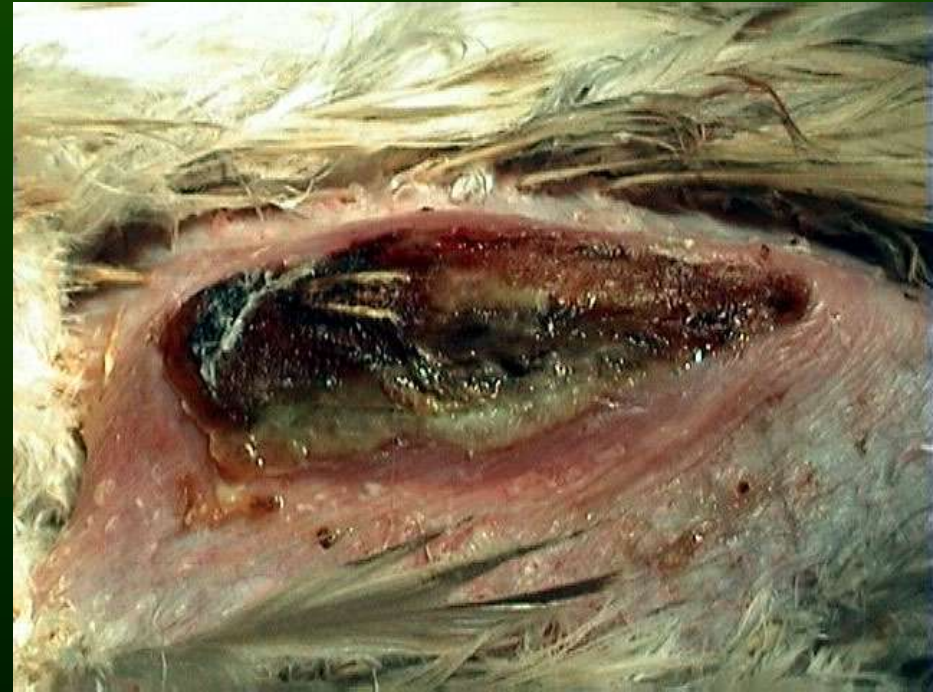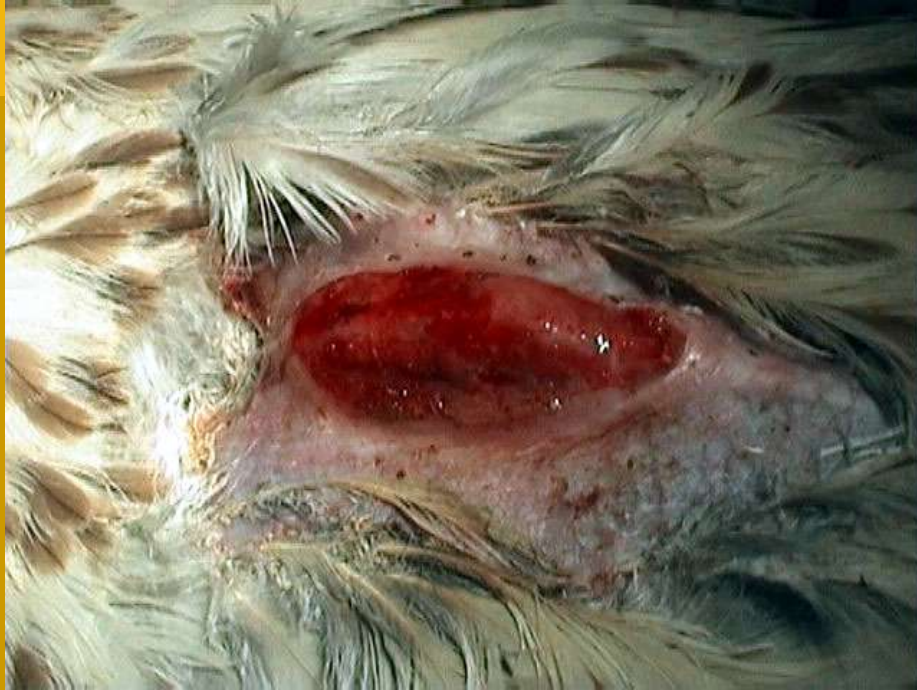Scissors beak

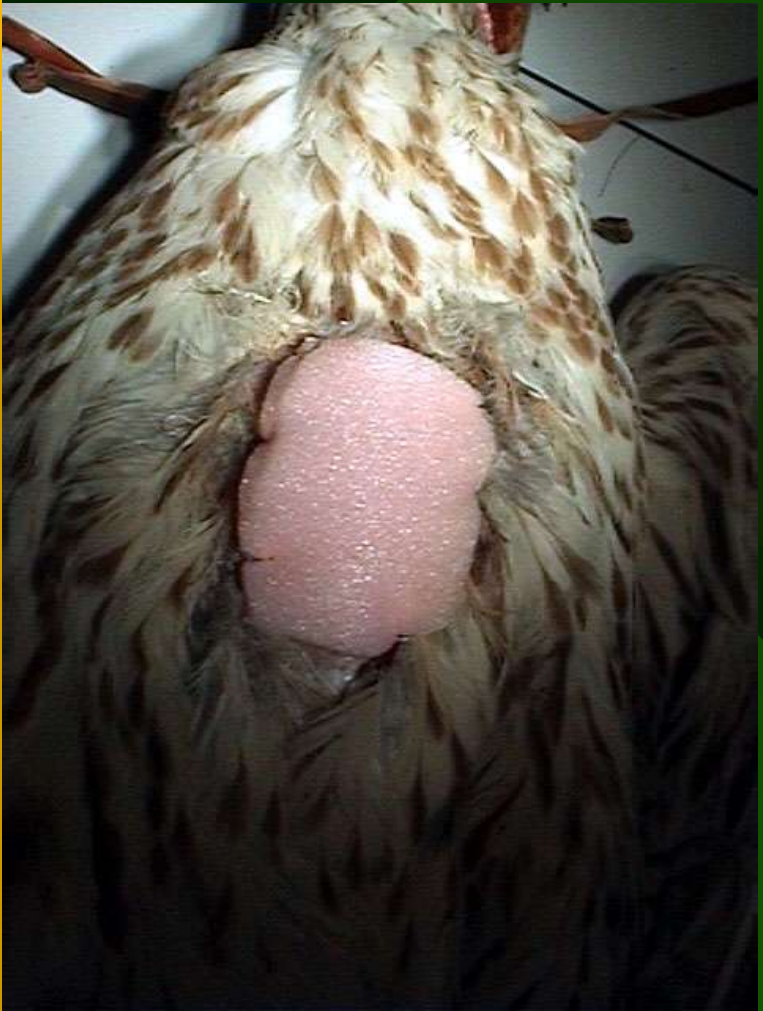
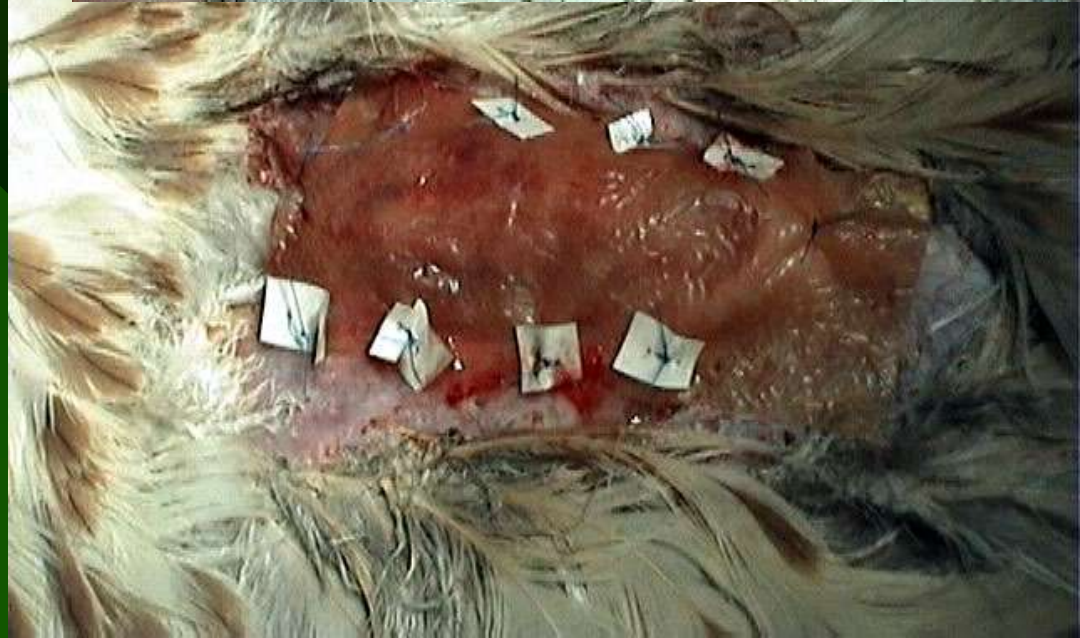


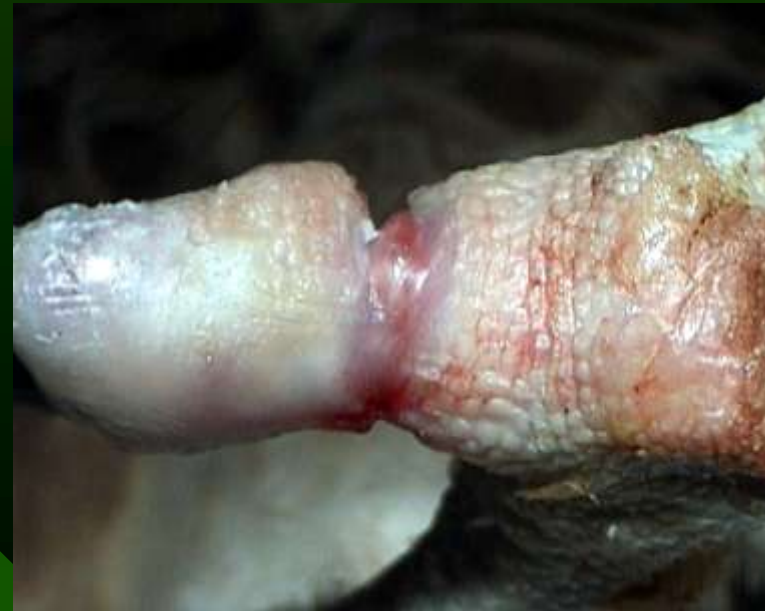
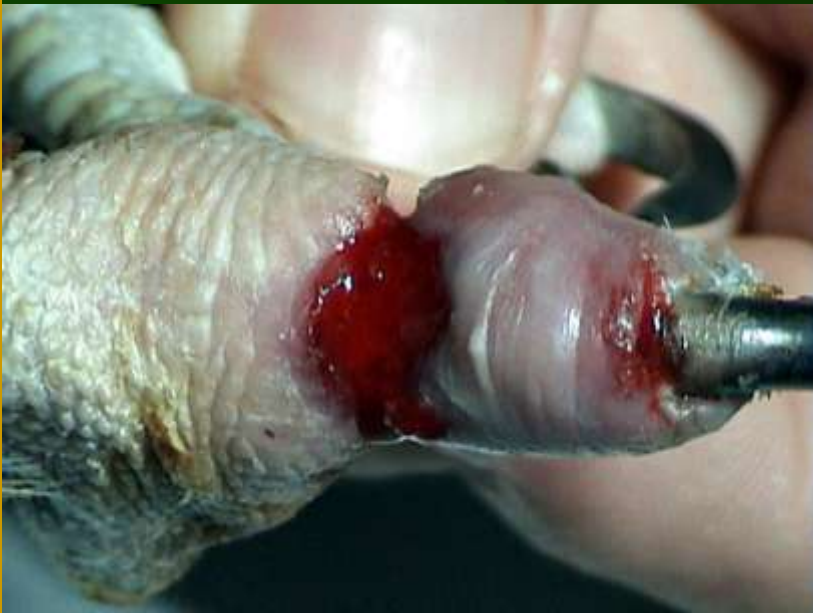
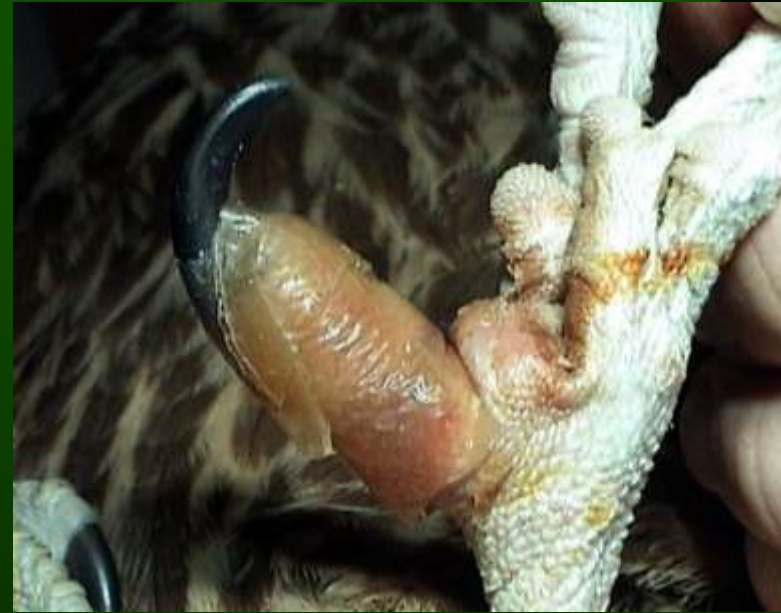
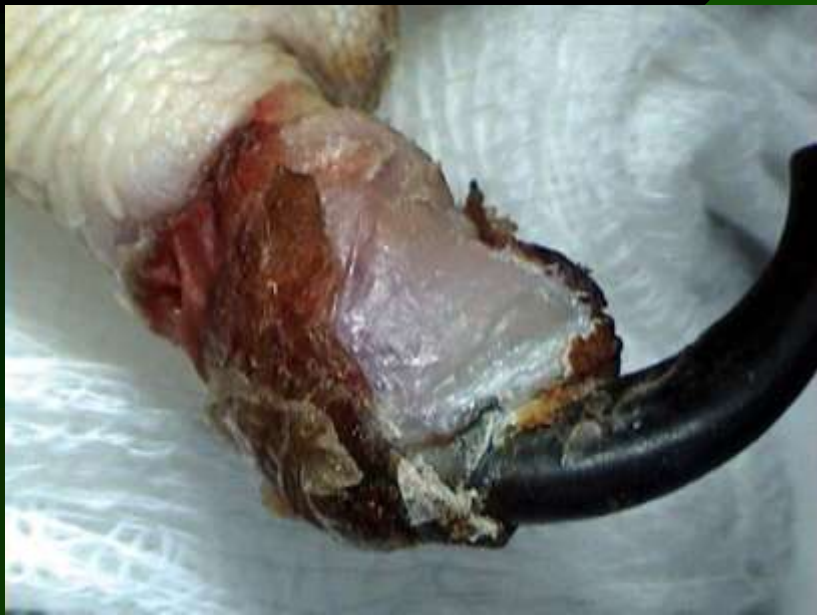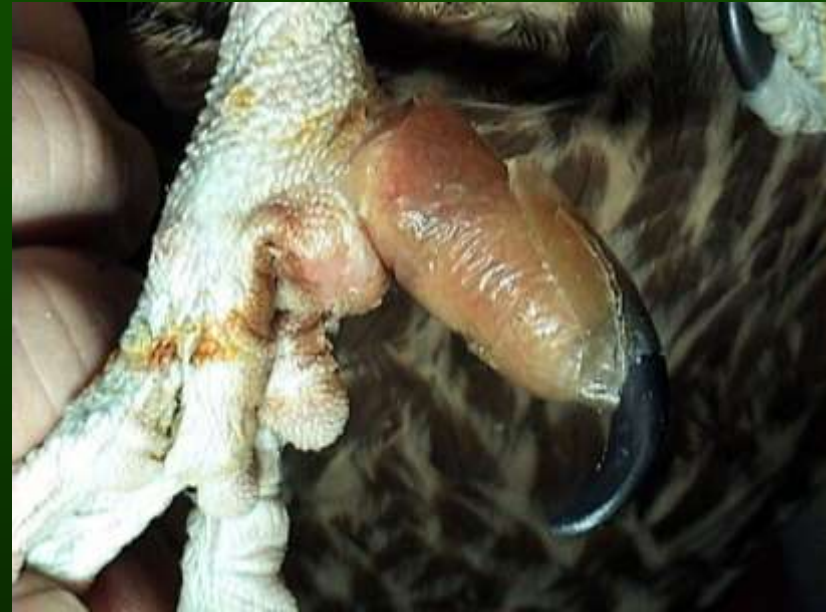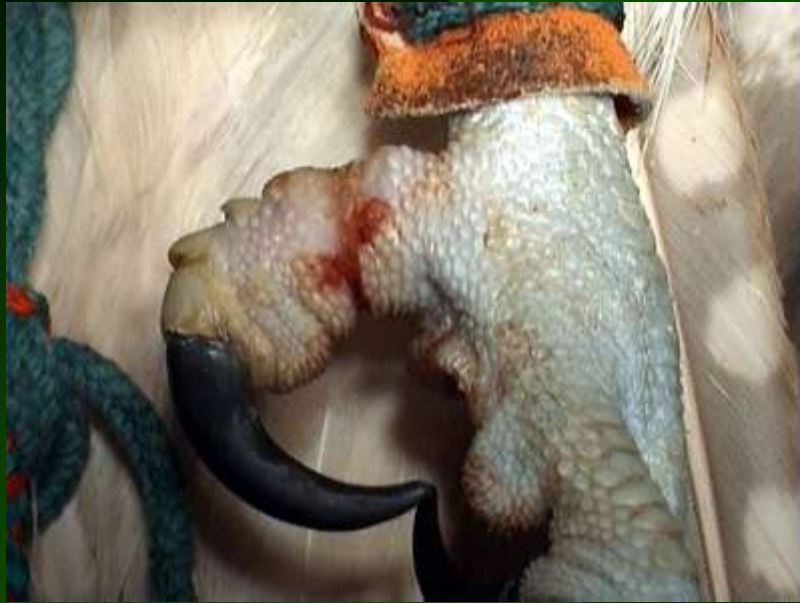Keel injury



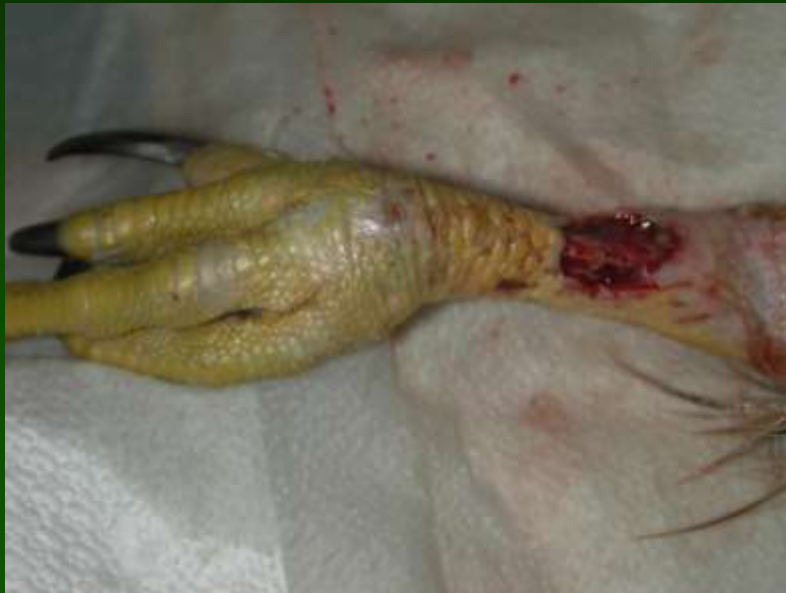



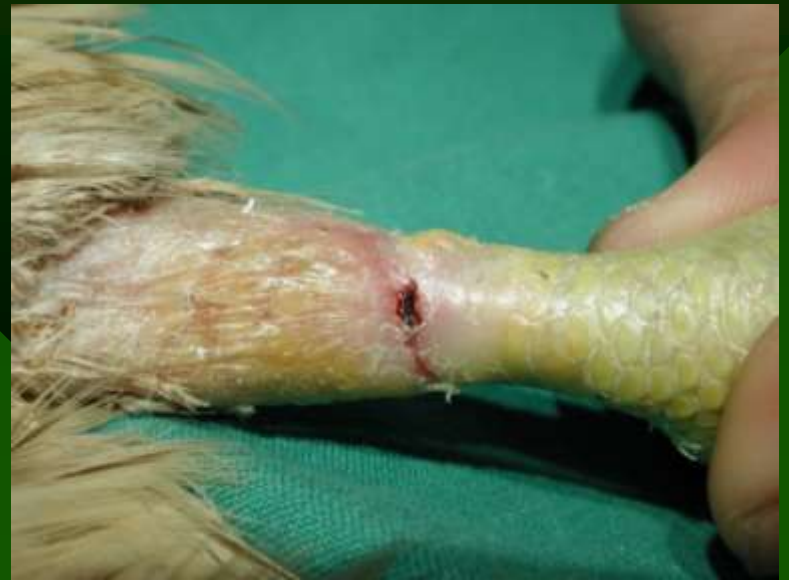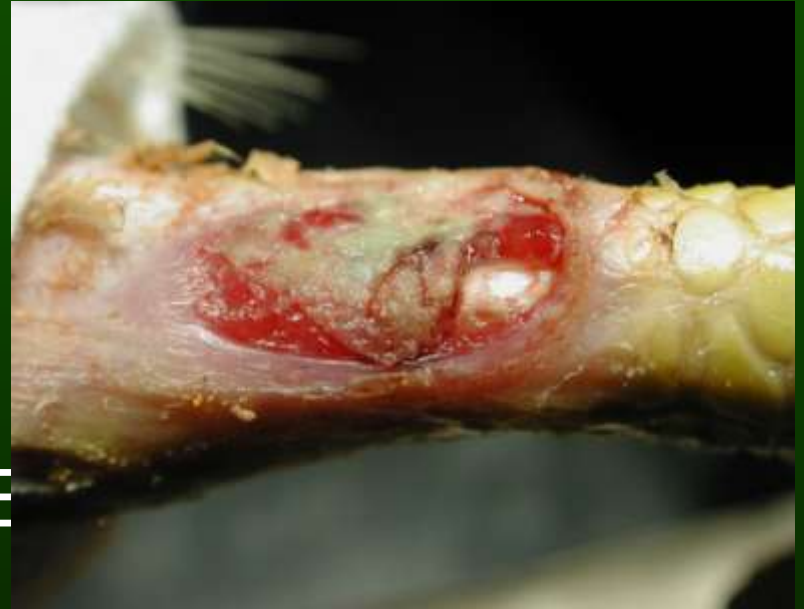•Hydrocolloid dressing



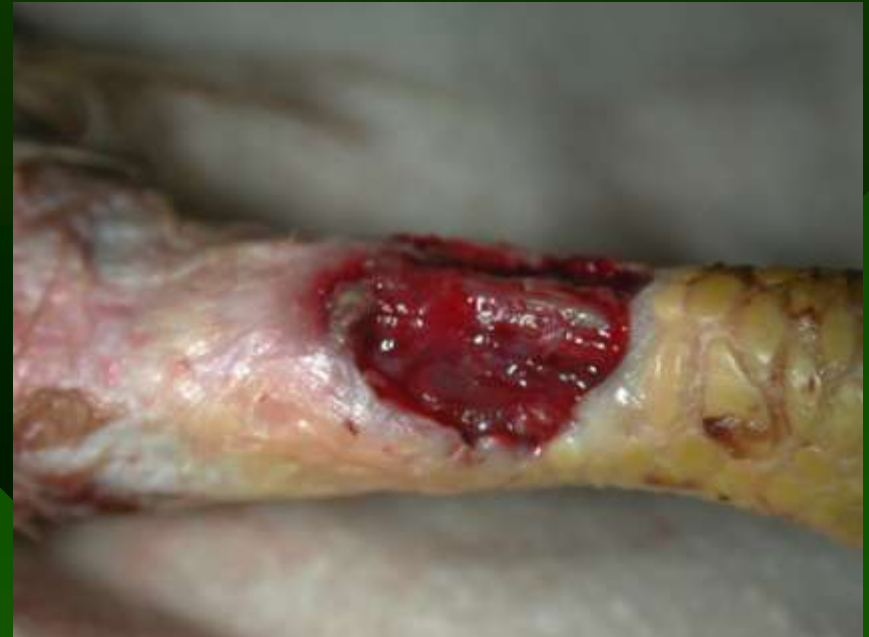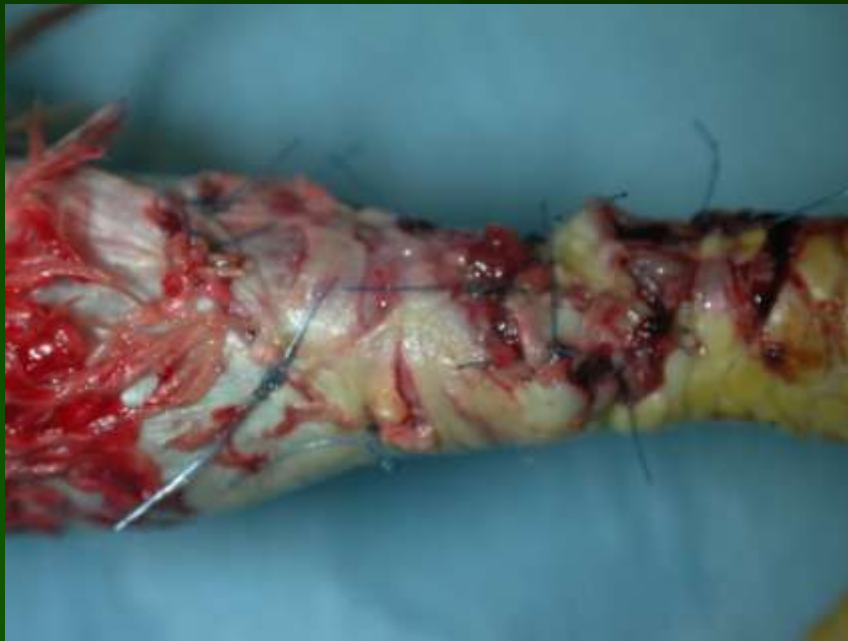Traumatic skin defects

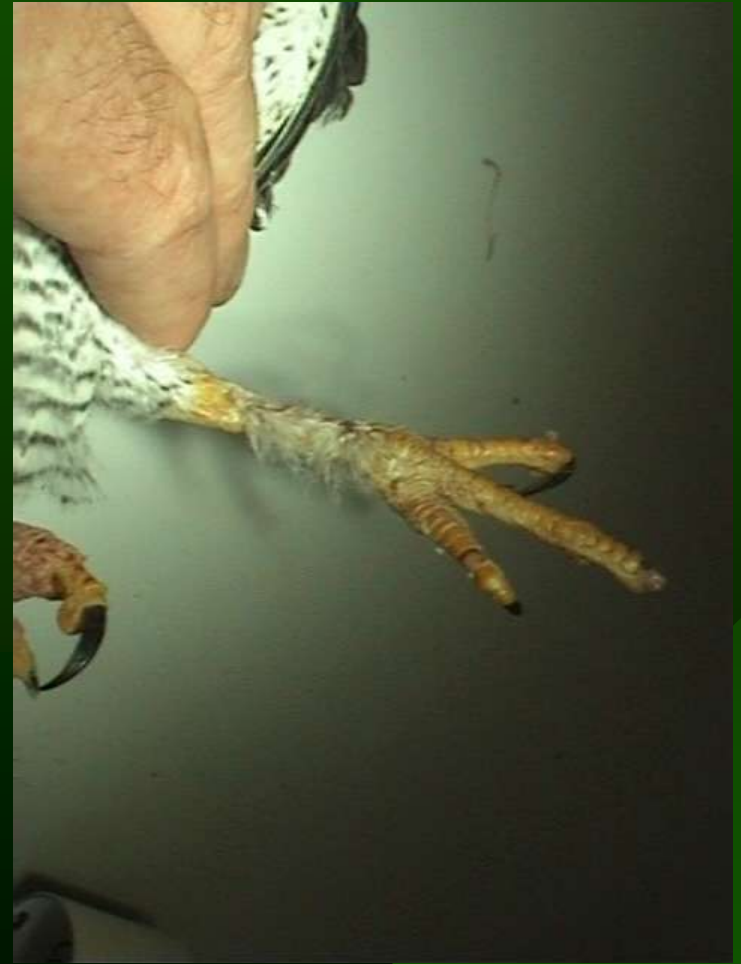
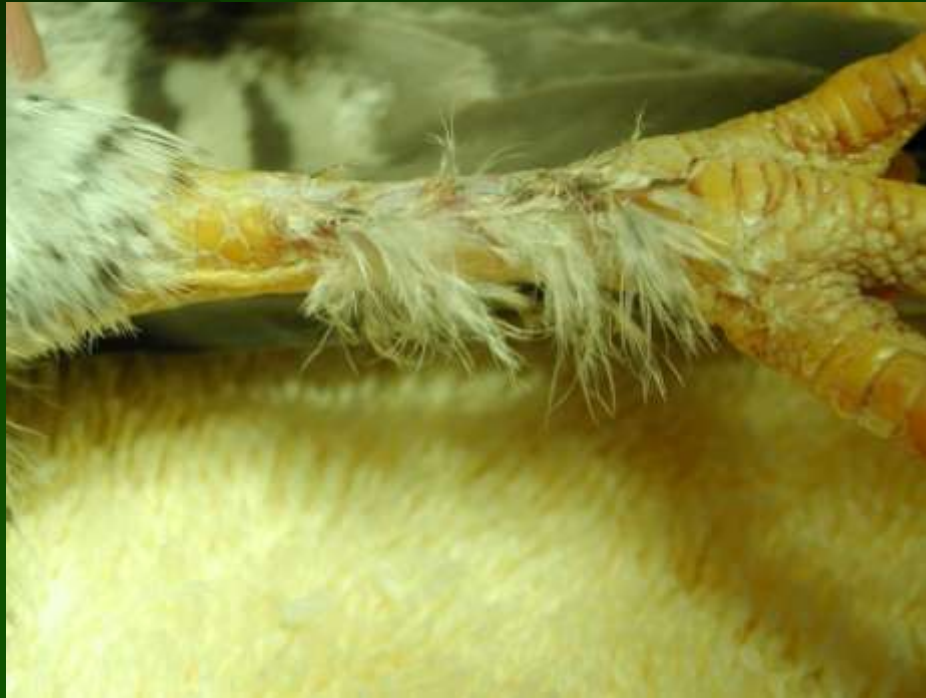
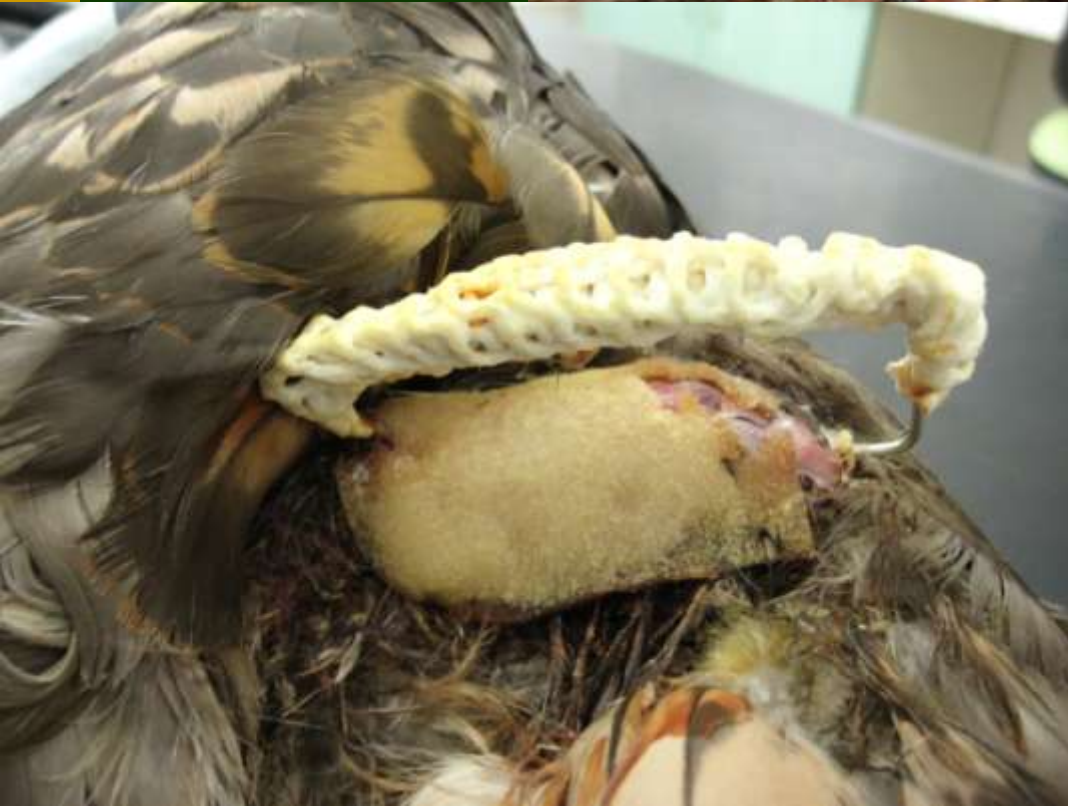SE



skin grafts
vascularized flaps
autologous transplants

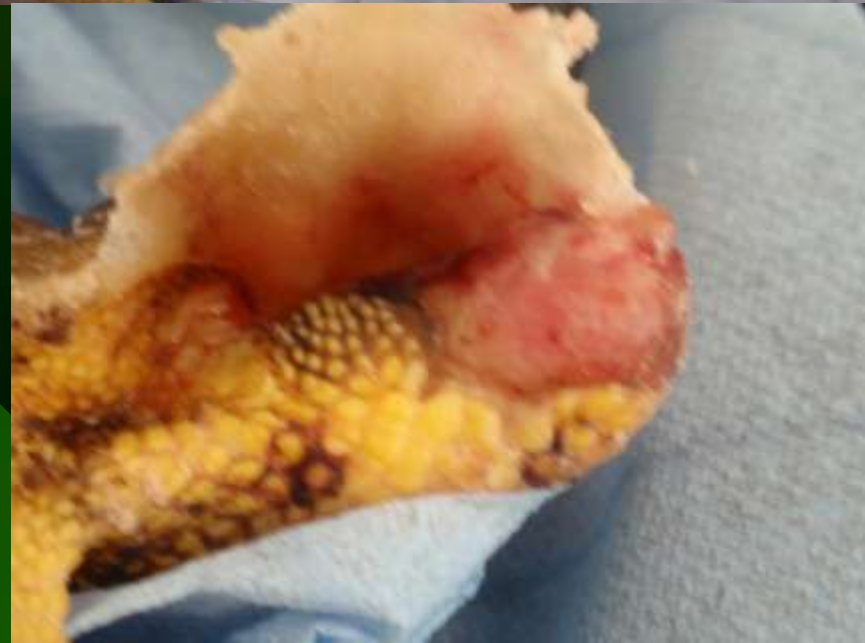
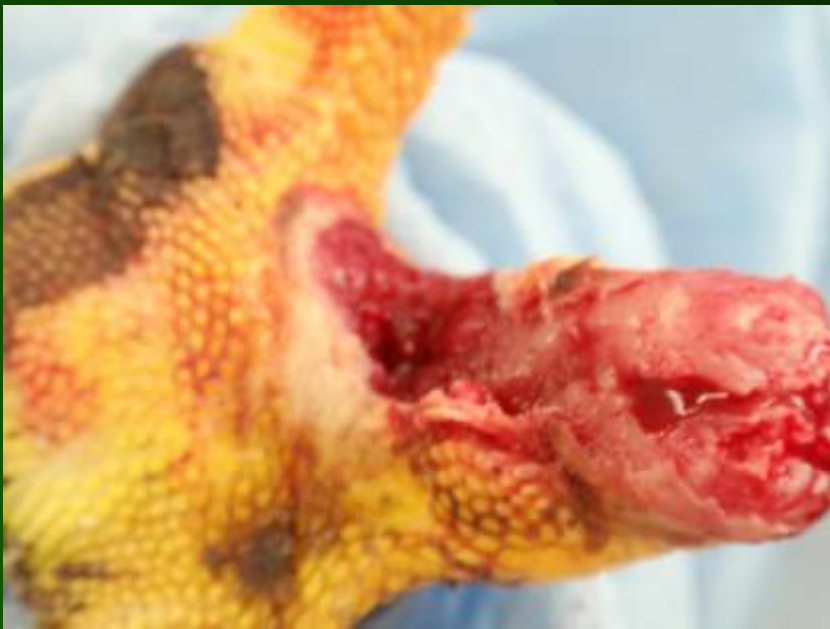


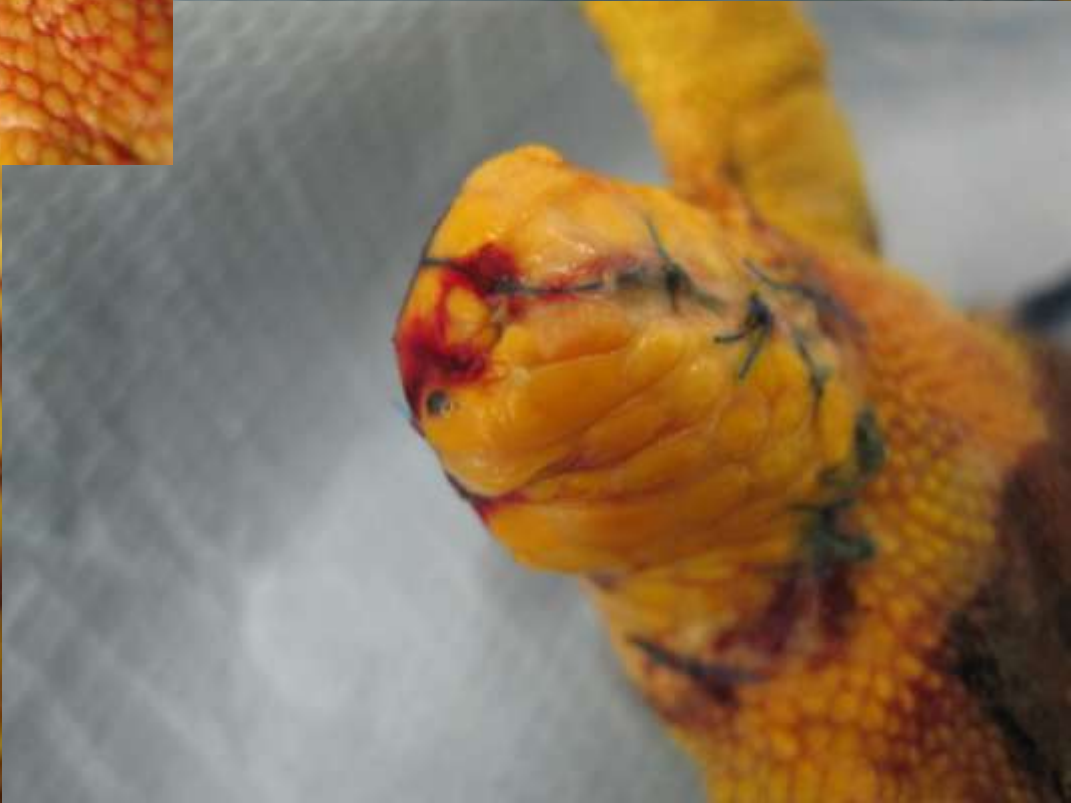
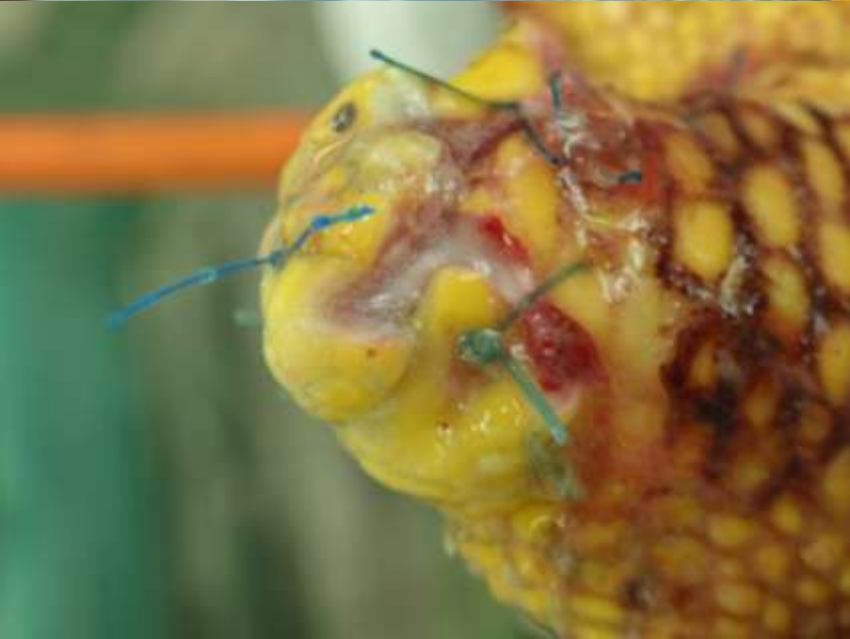
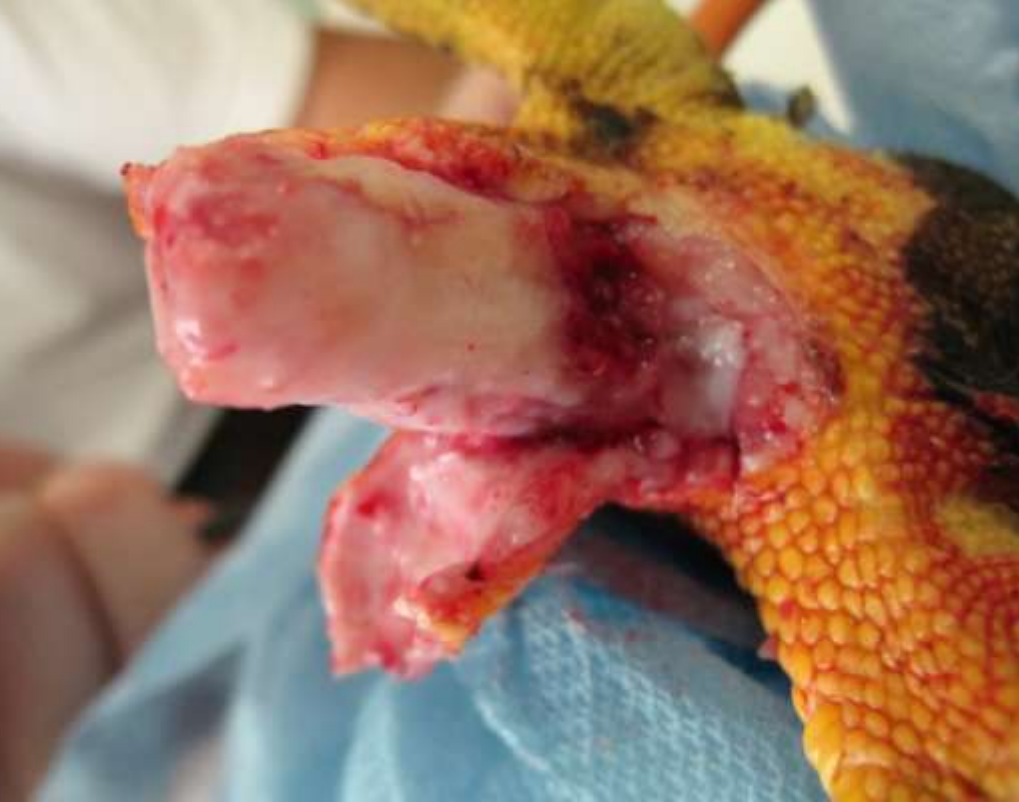•Skin flap
with PRPT

*Platelet rich
plasma treatment*

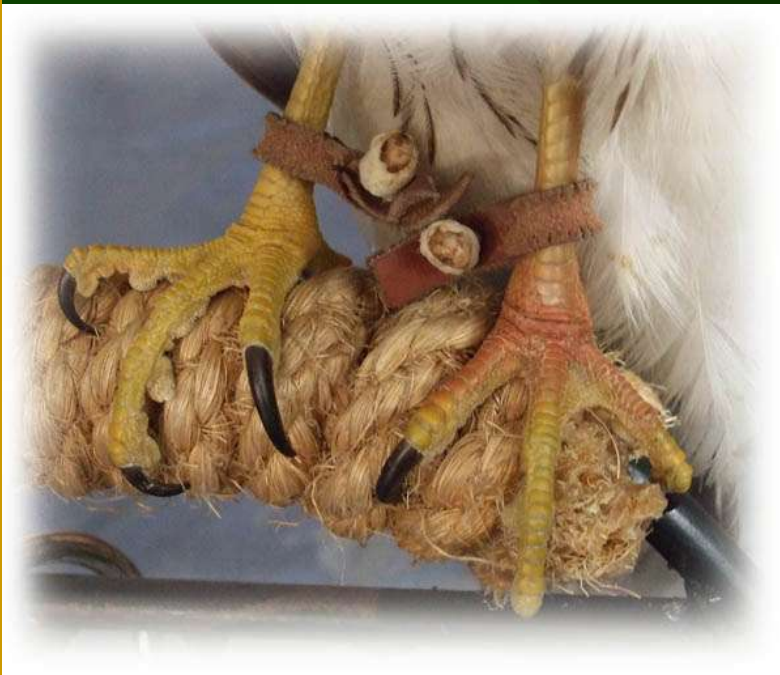


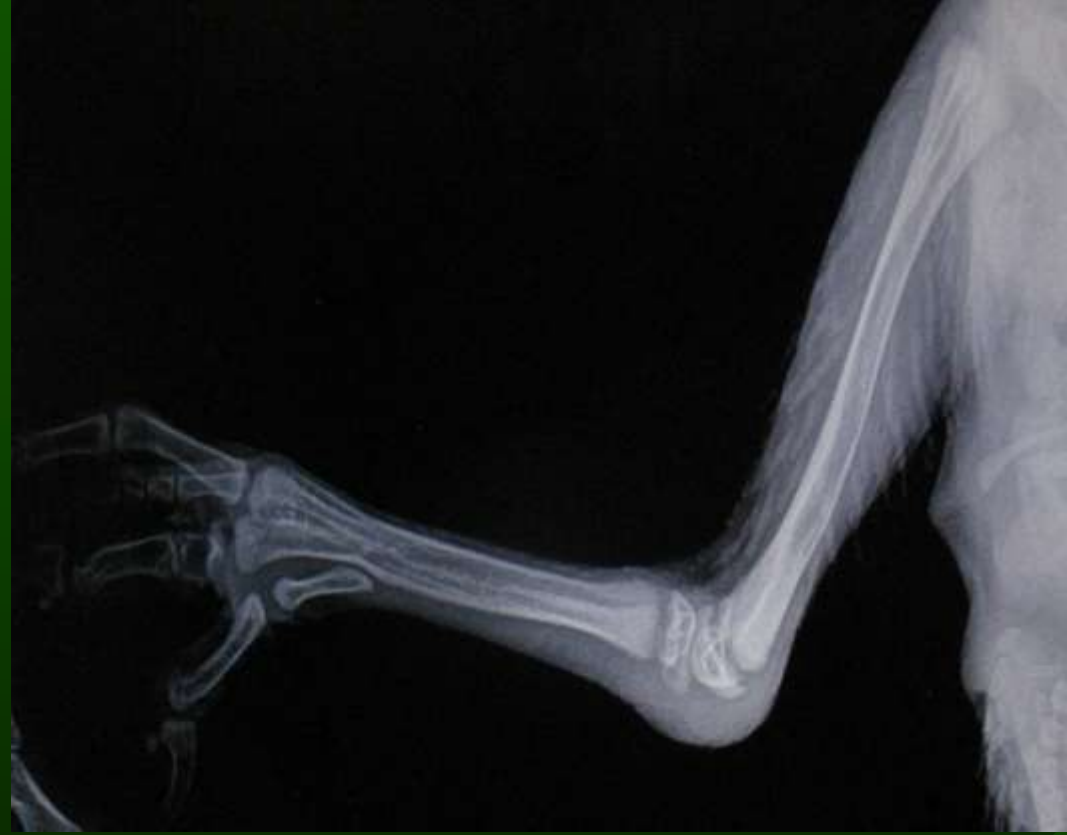
Skin flap after 1 year

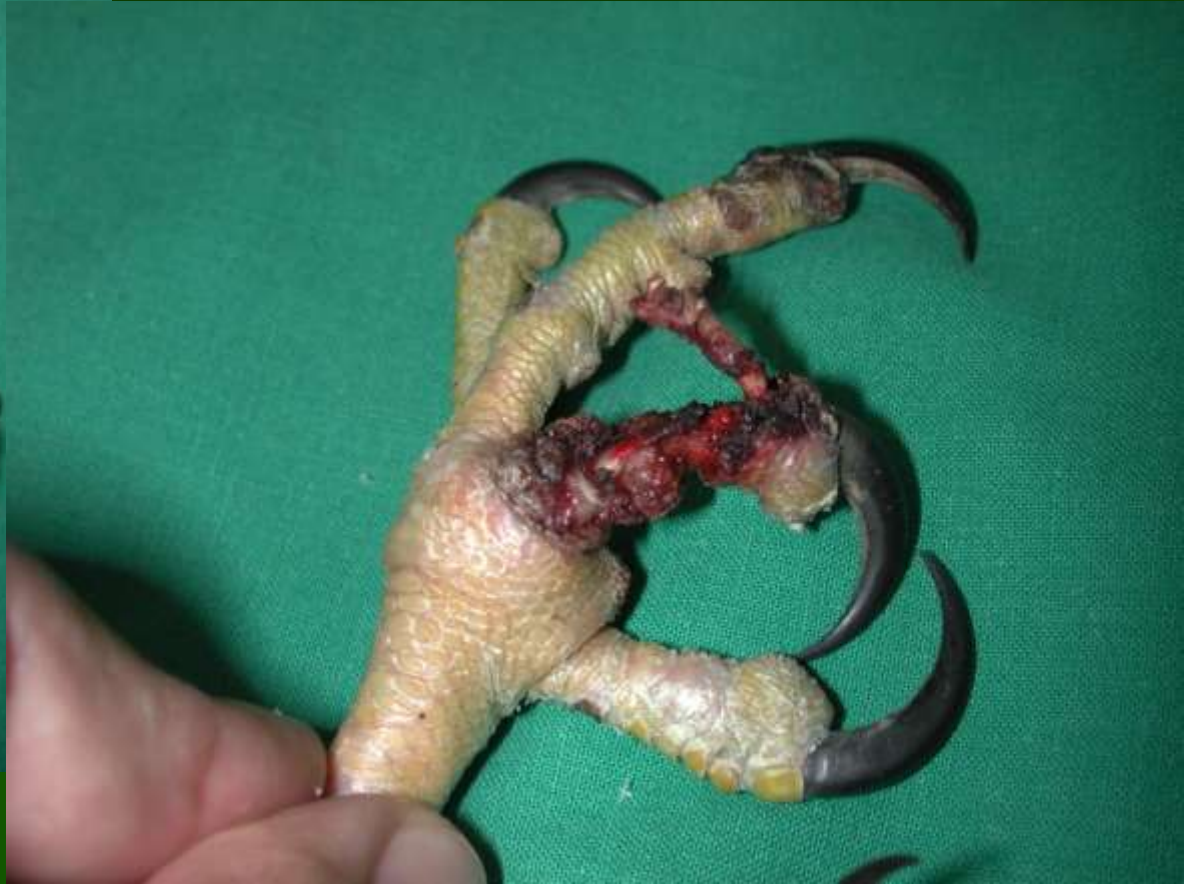
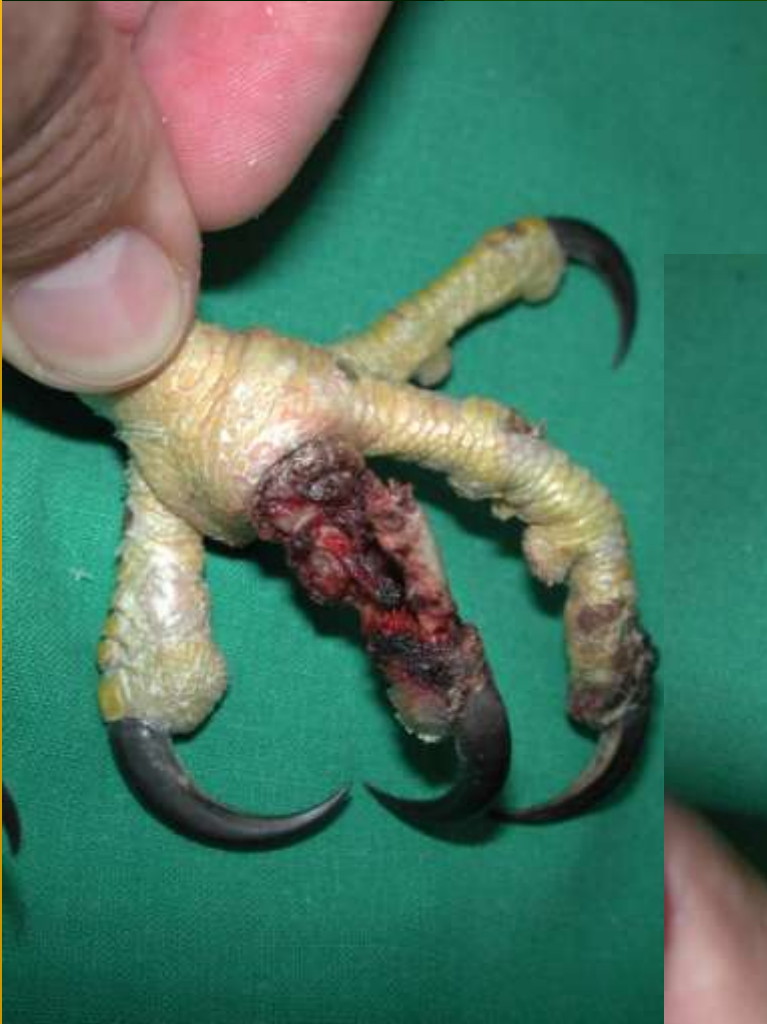
Digit I. avulsion tendo-sinovitis





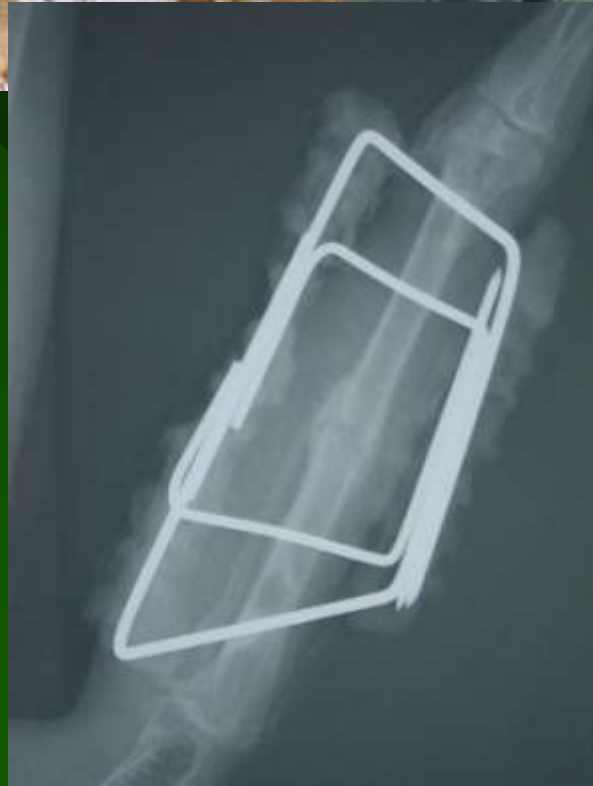Automutilation

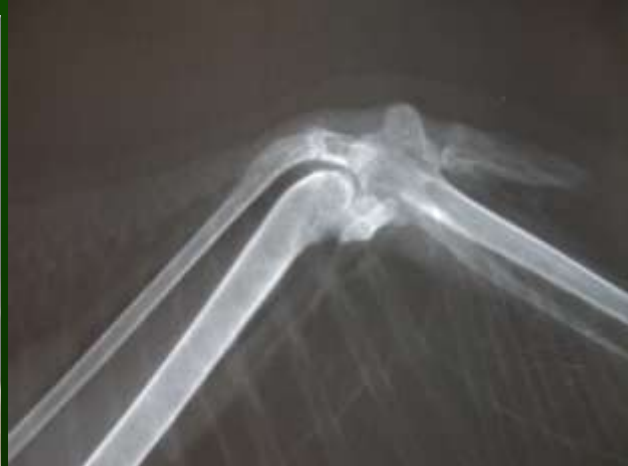
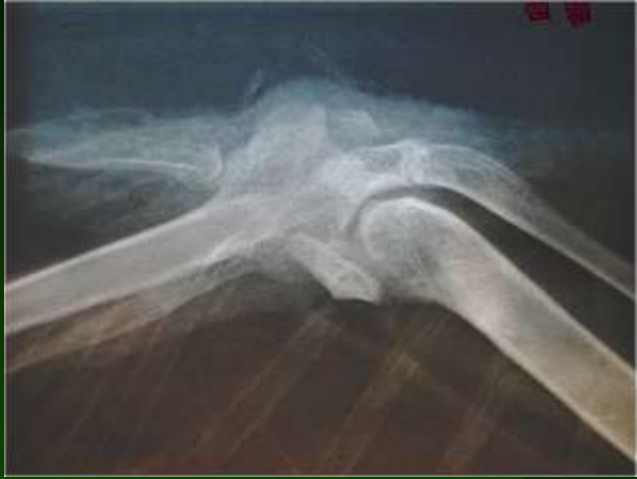
Injuries by prey

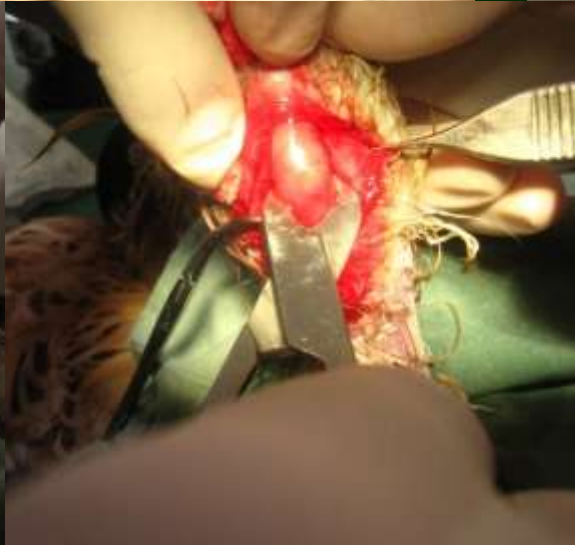
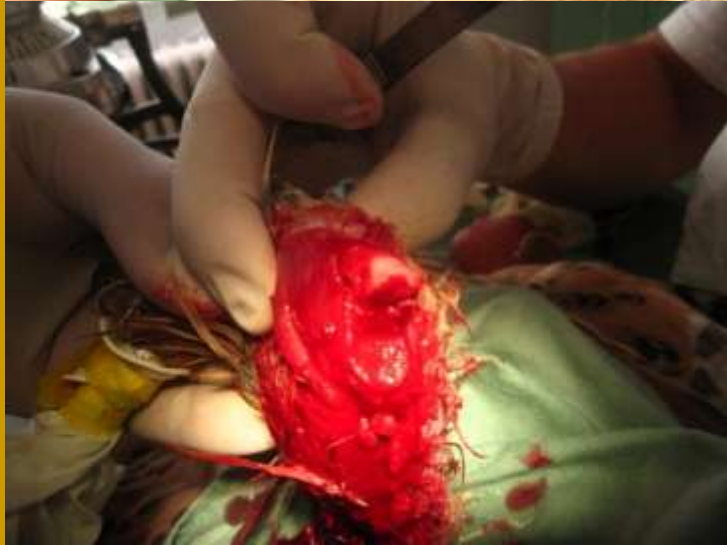
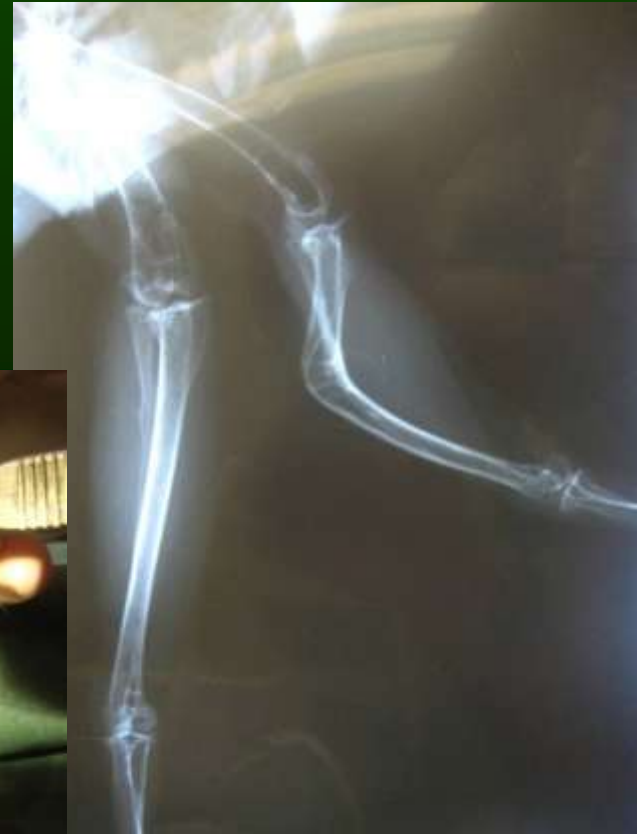
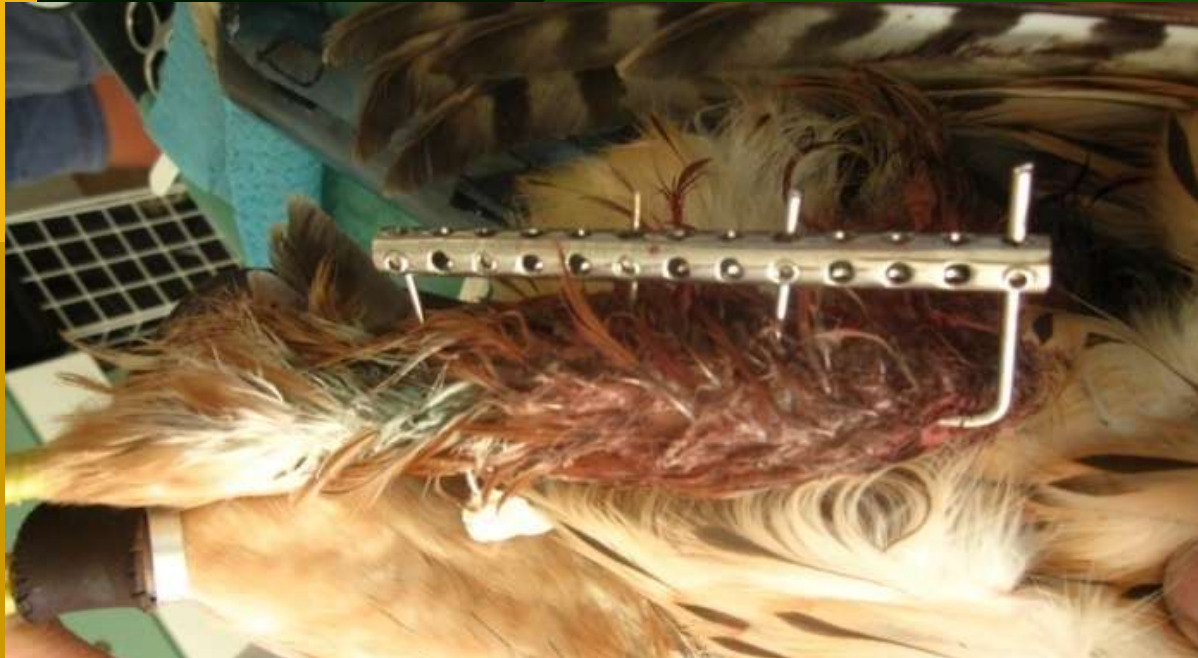




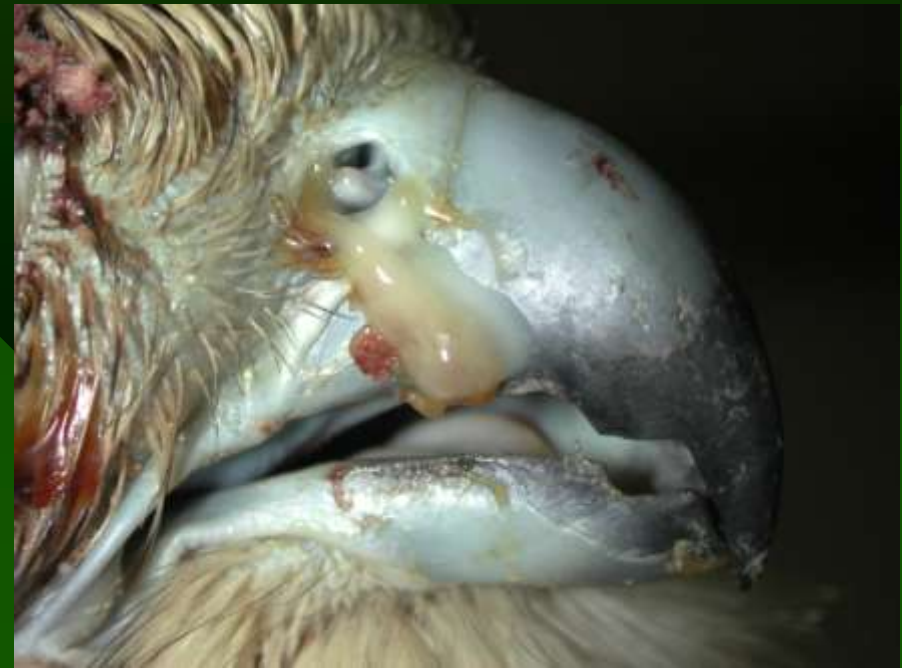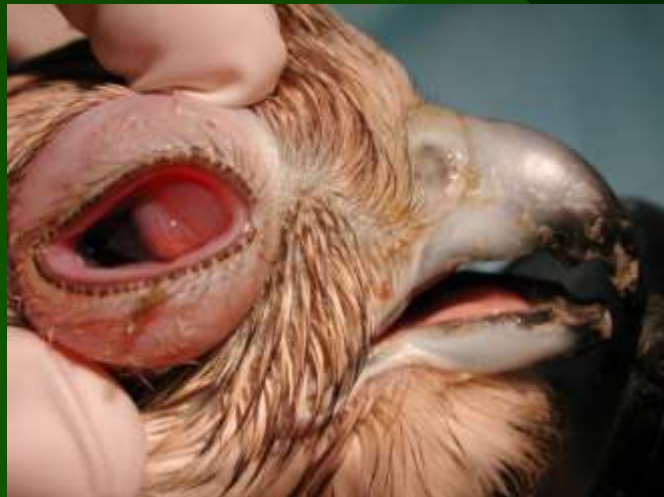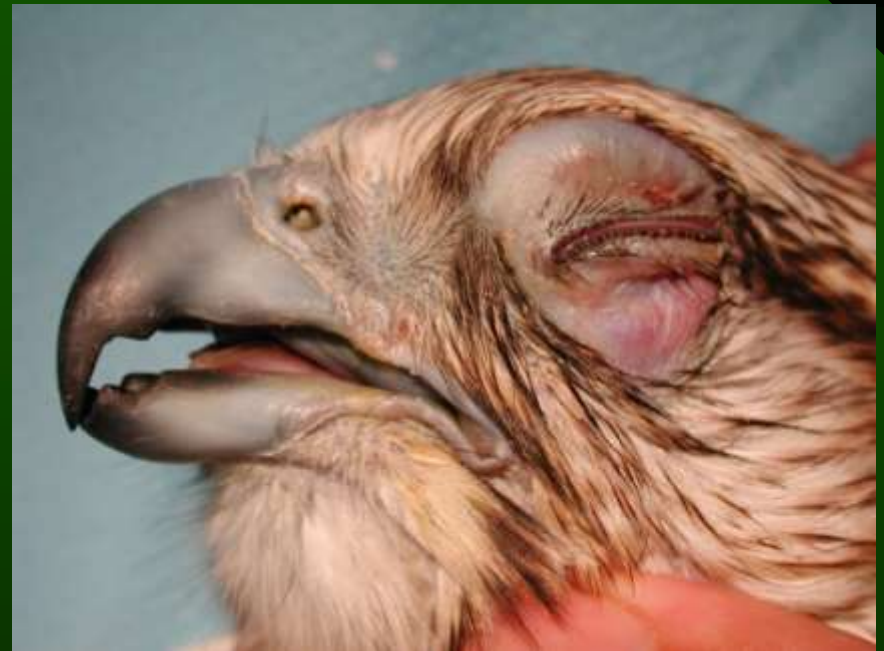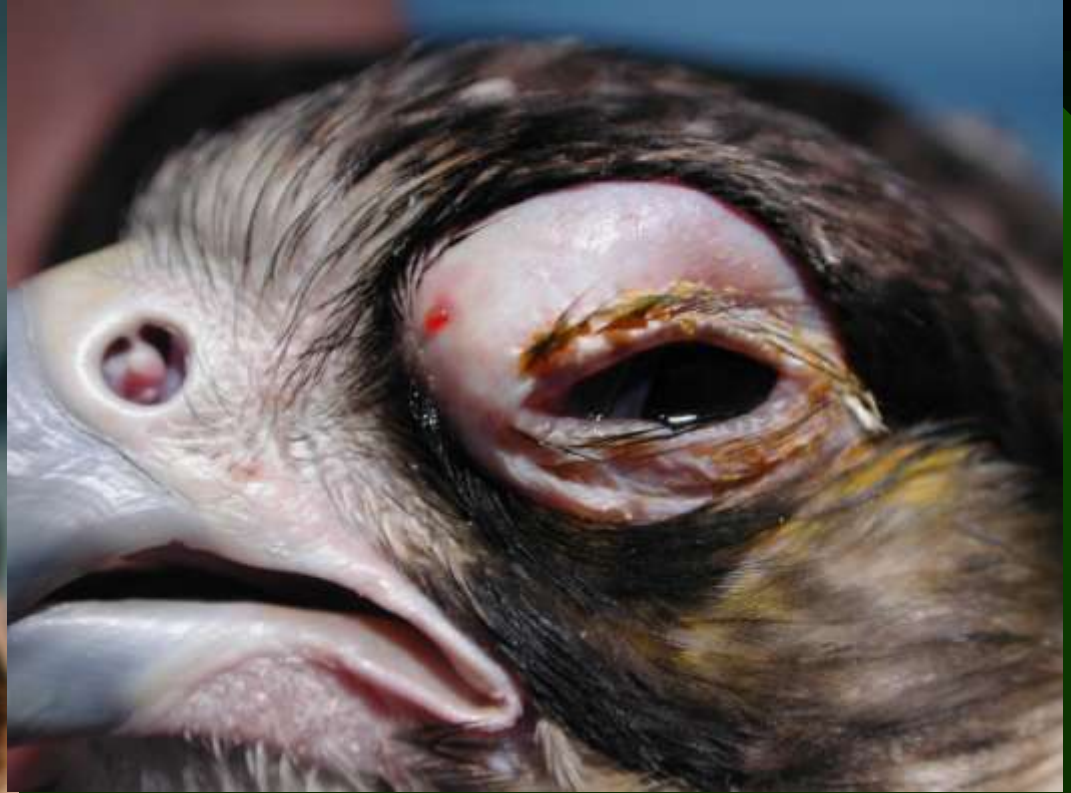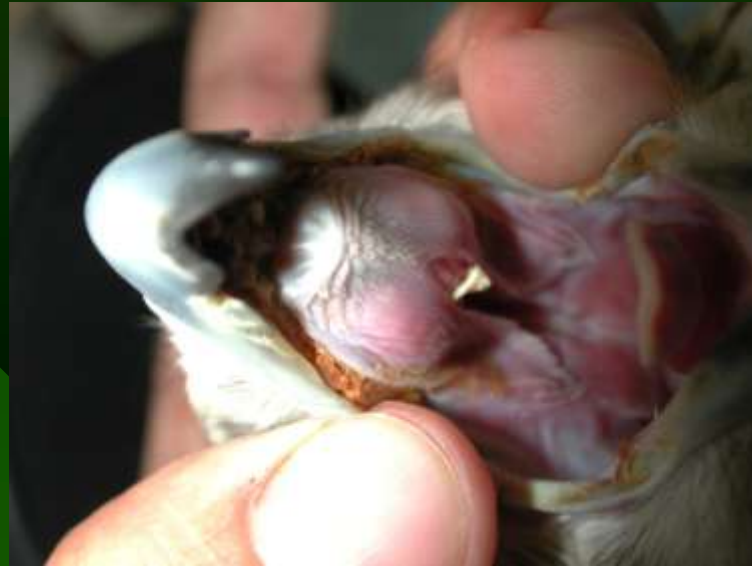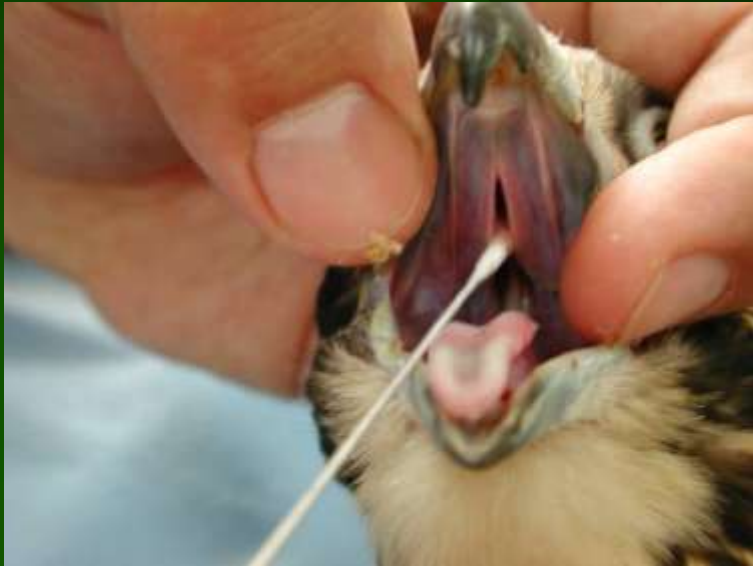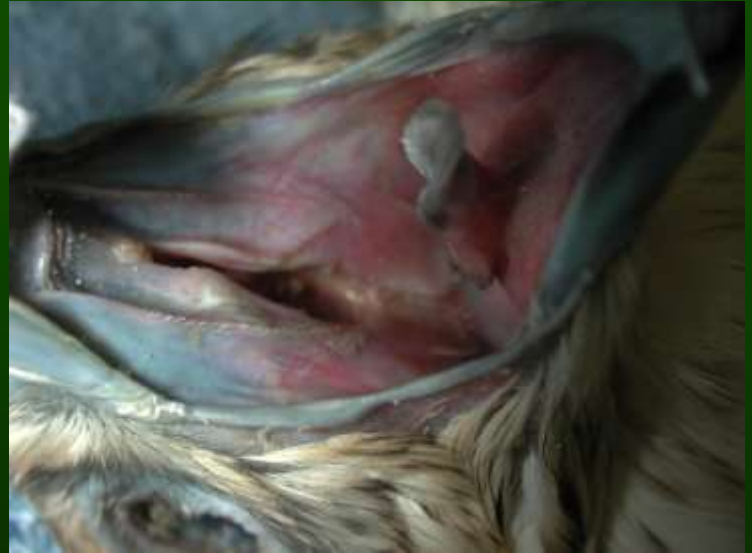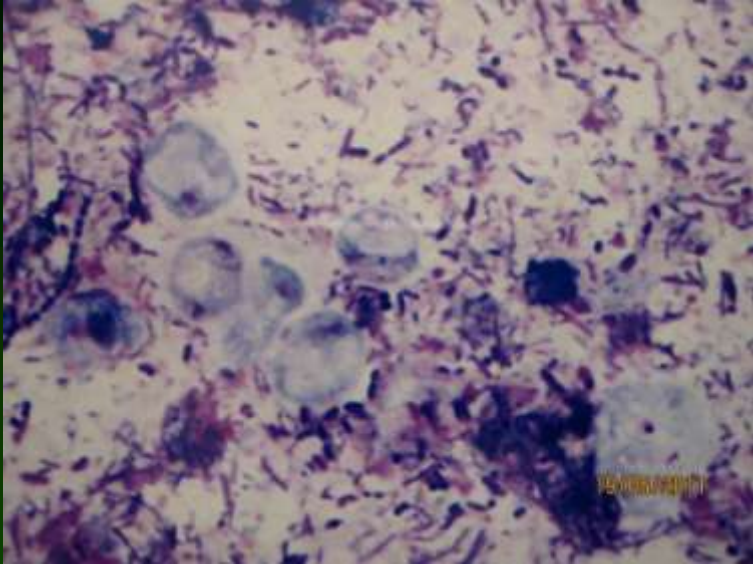
Low calcium diet

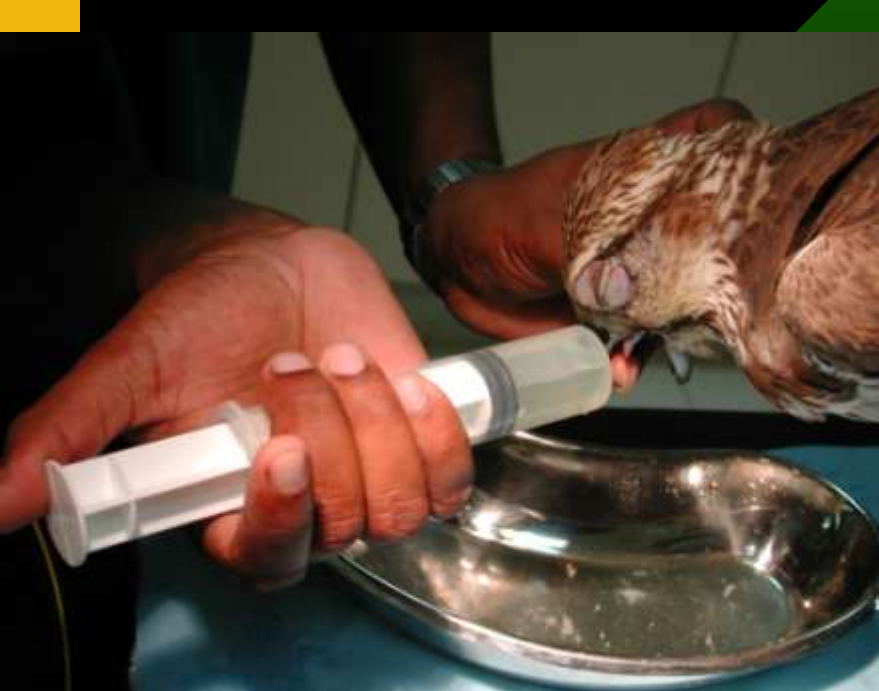

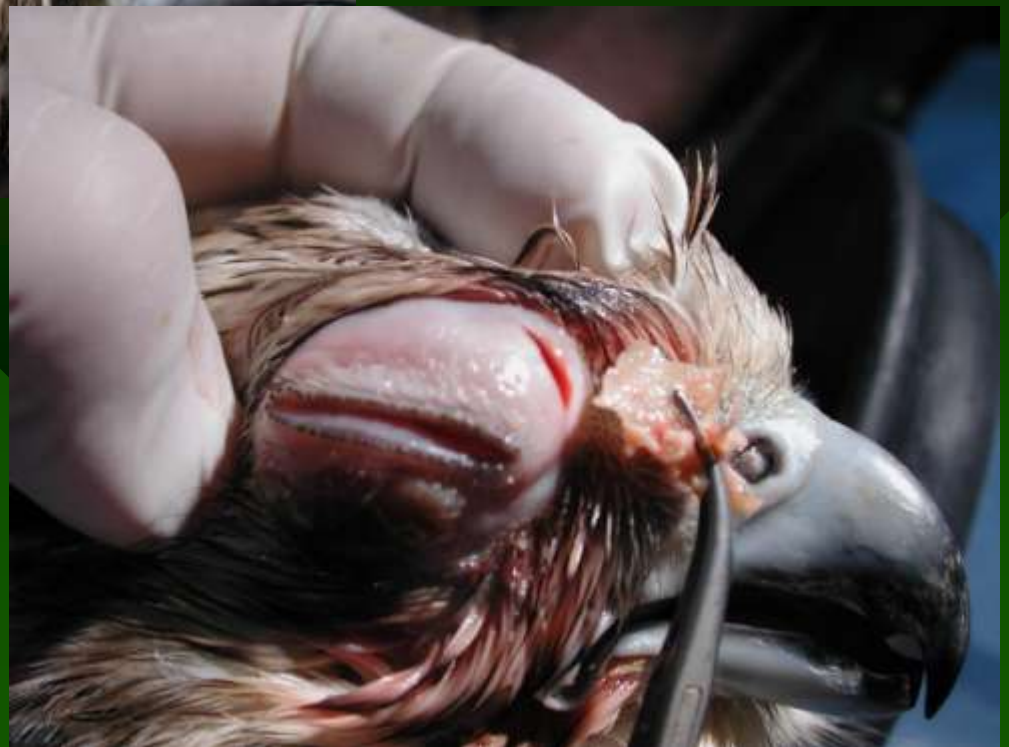
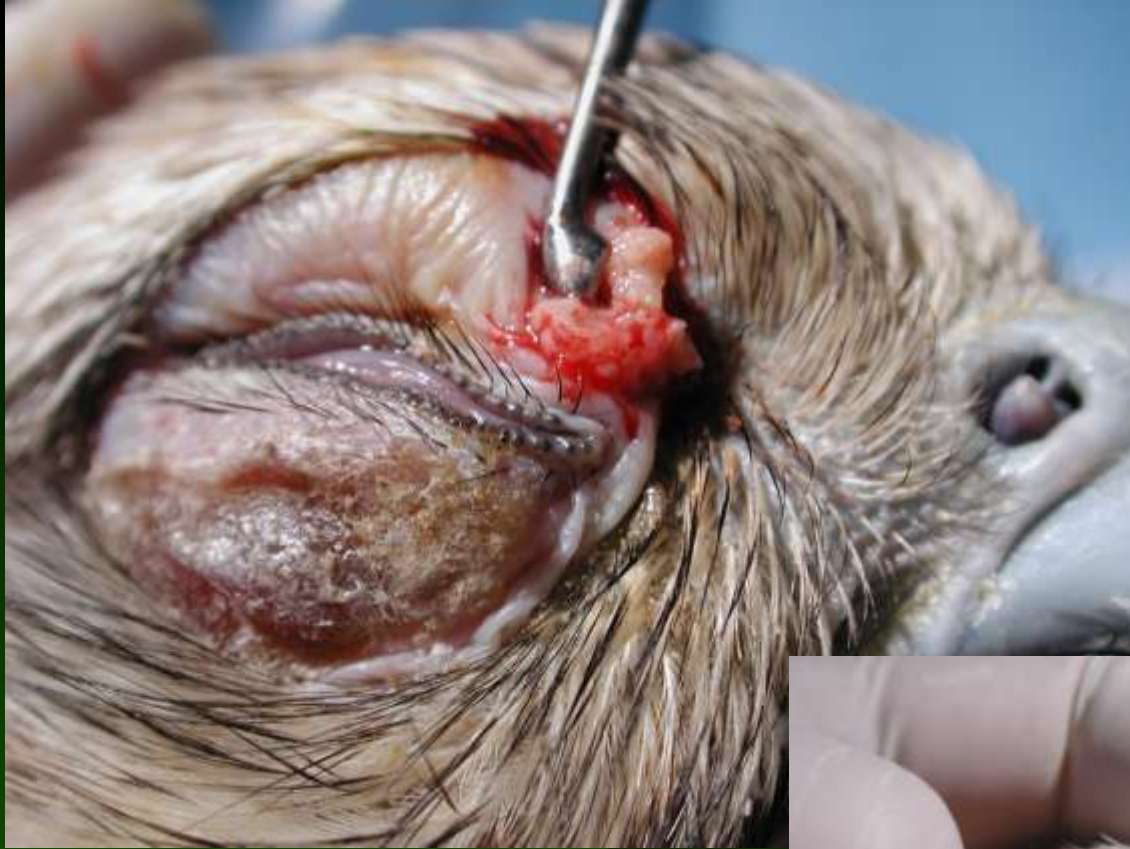Sinusitis

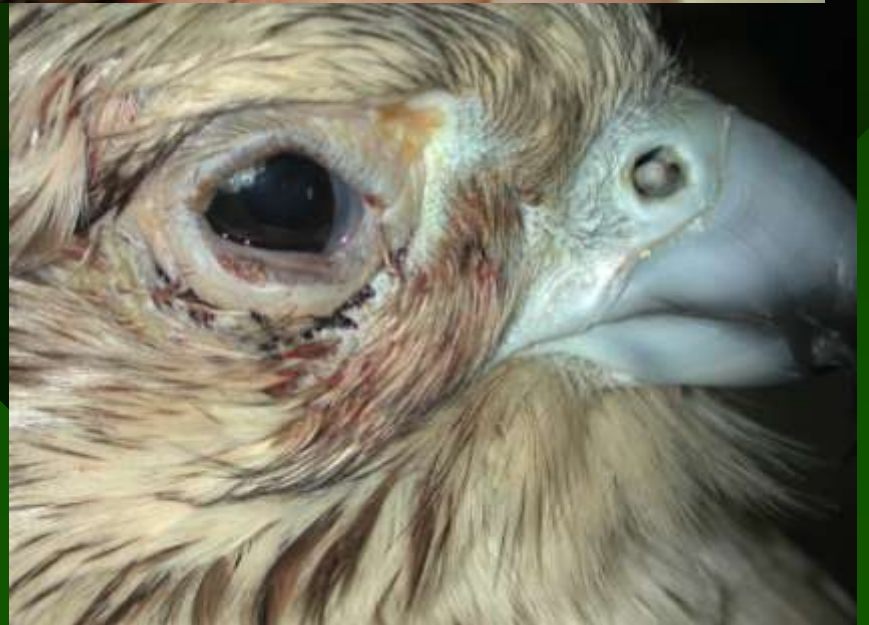
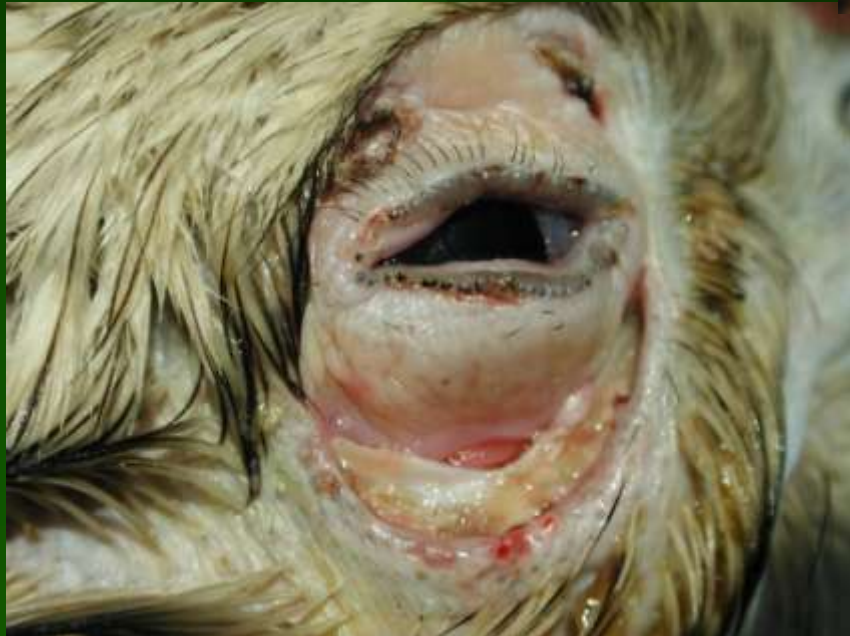
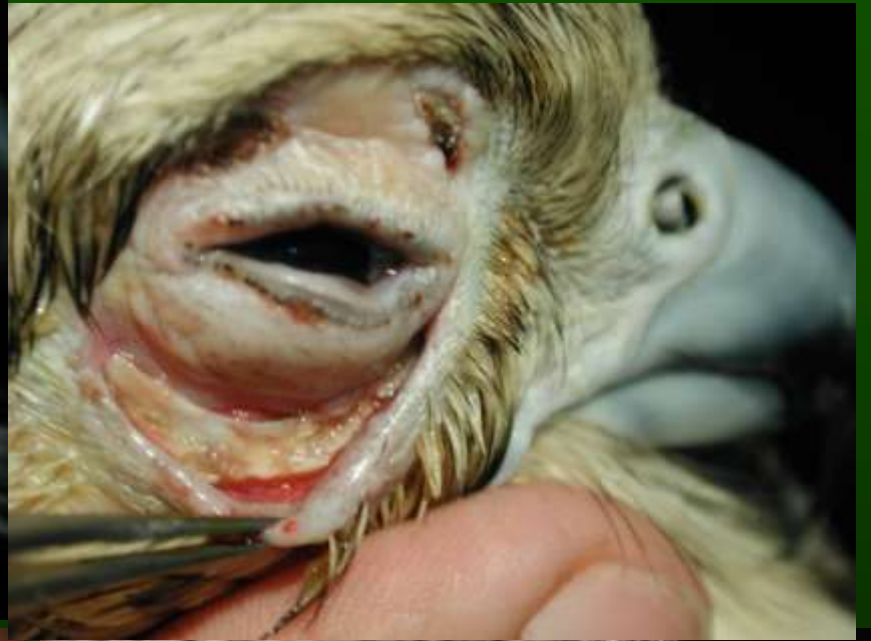
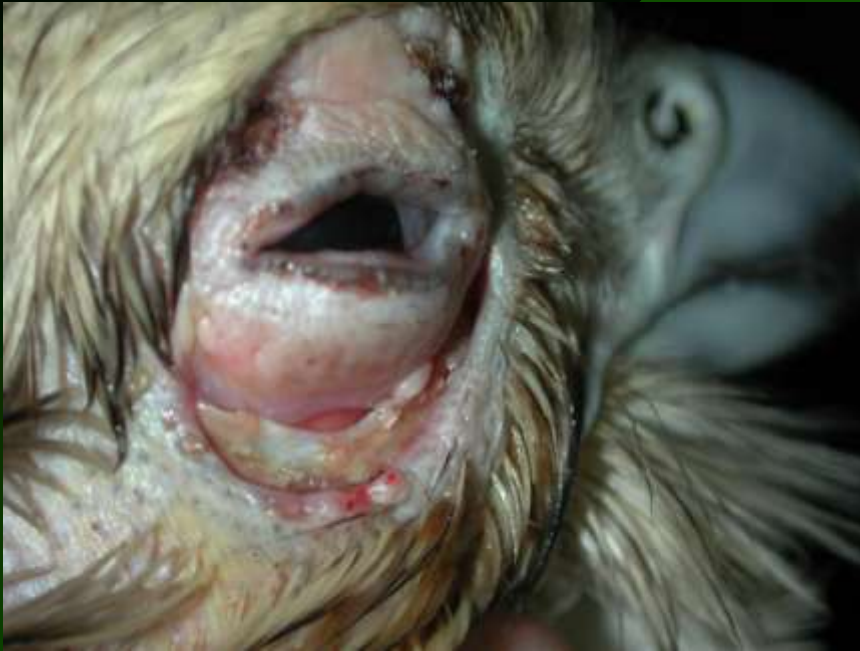


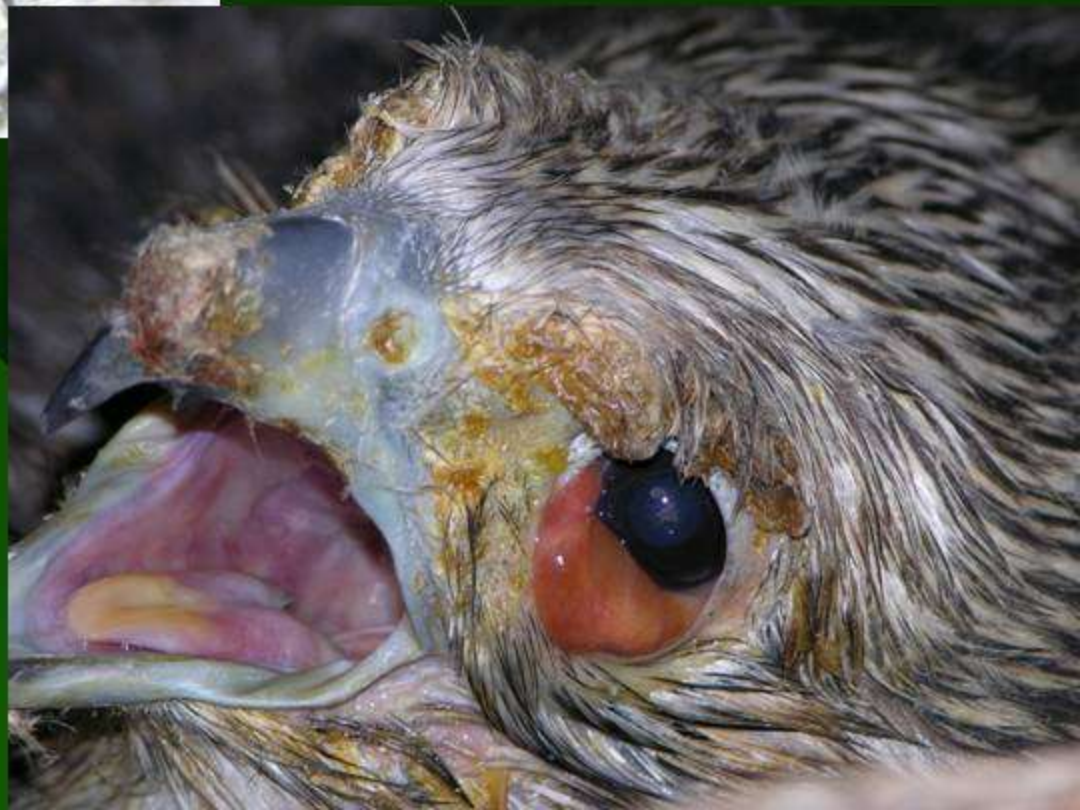
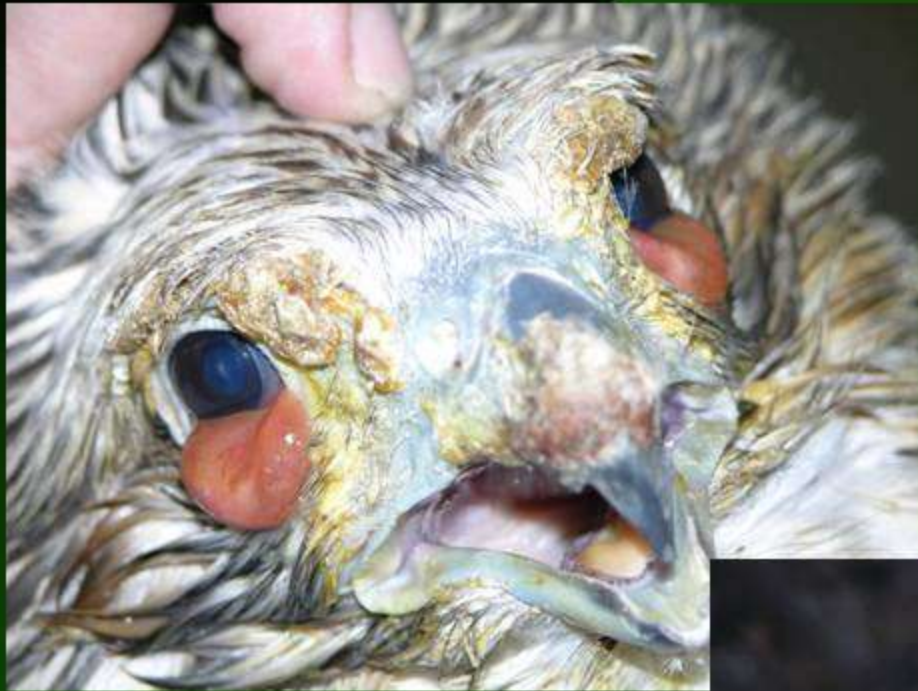




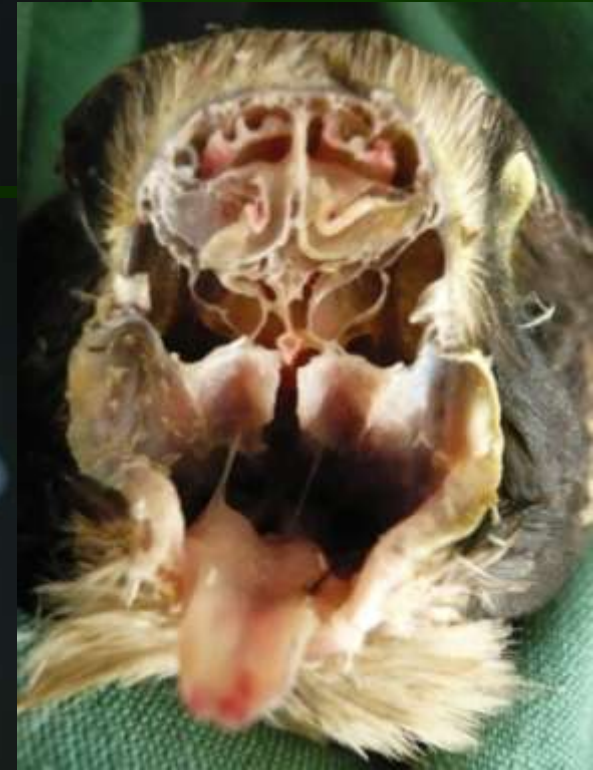
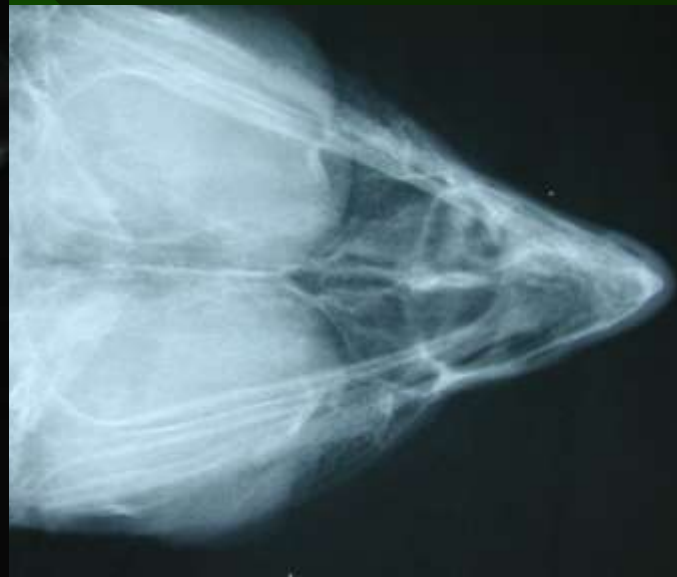
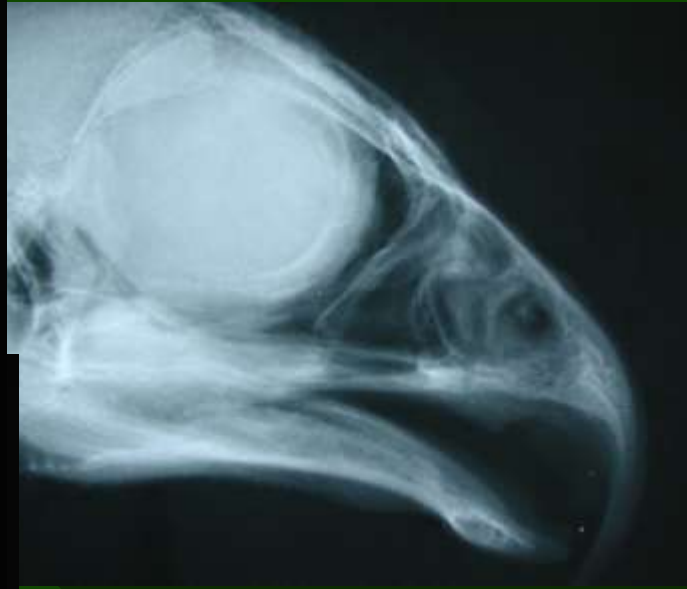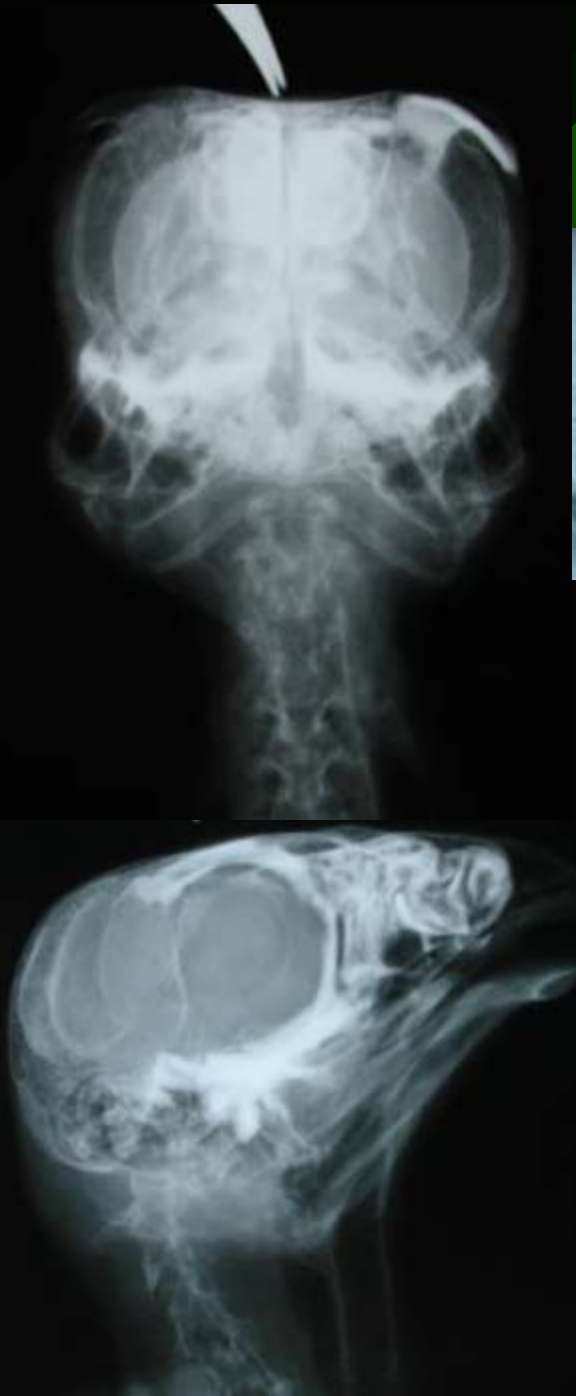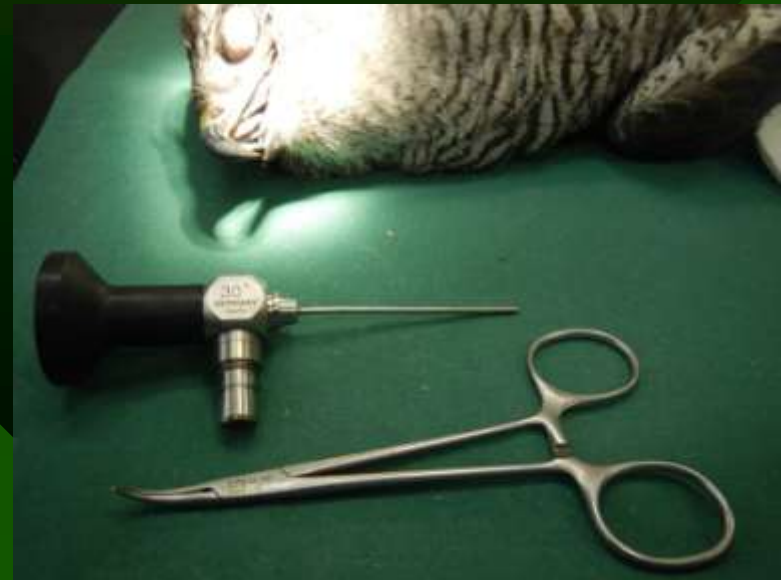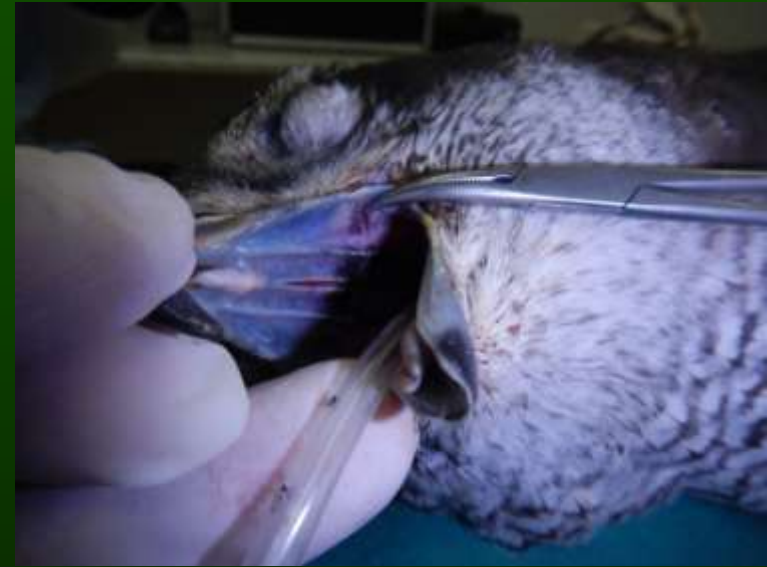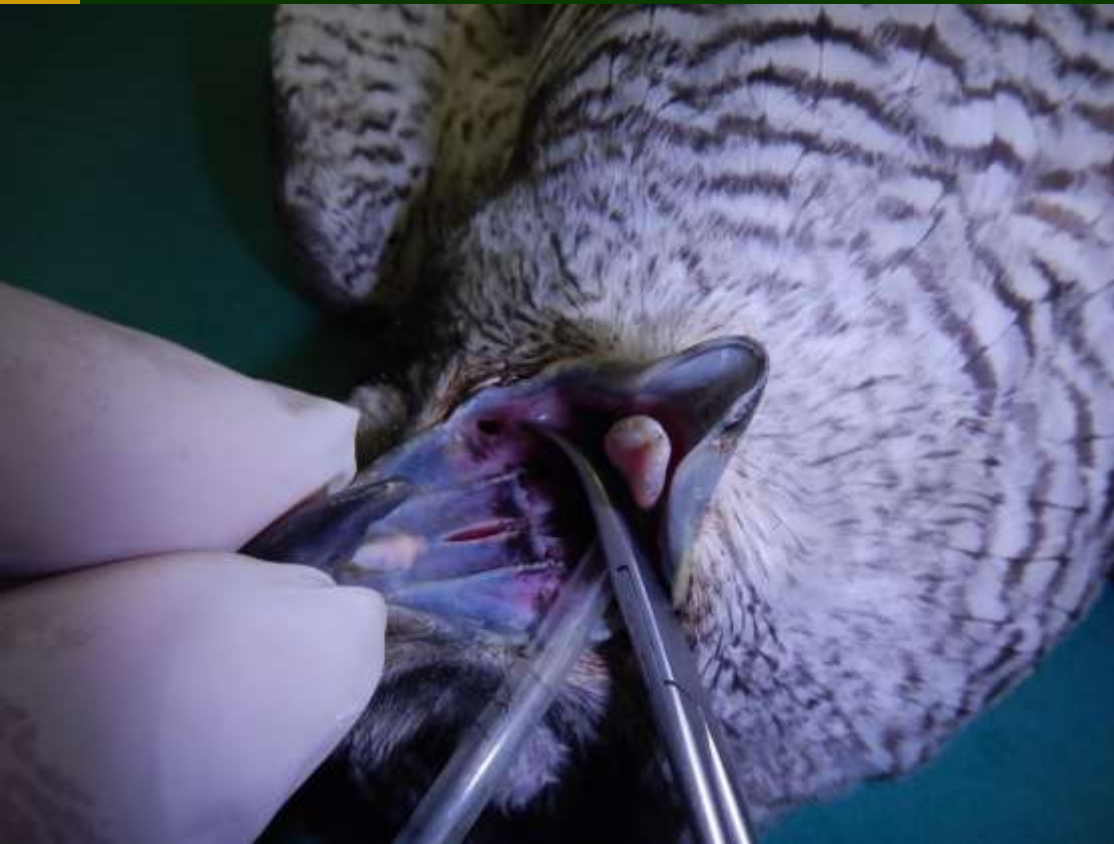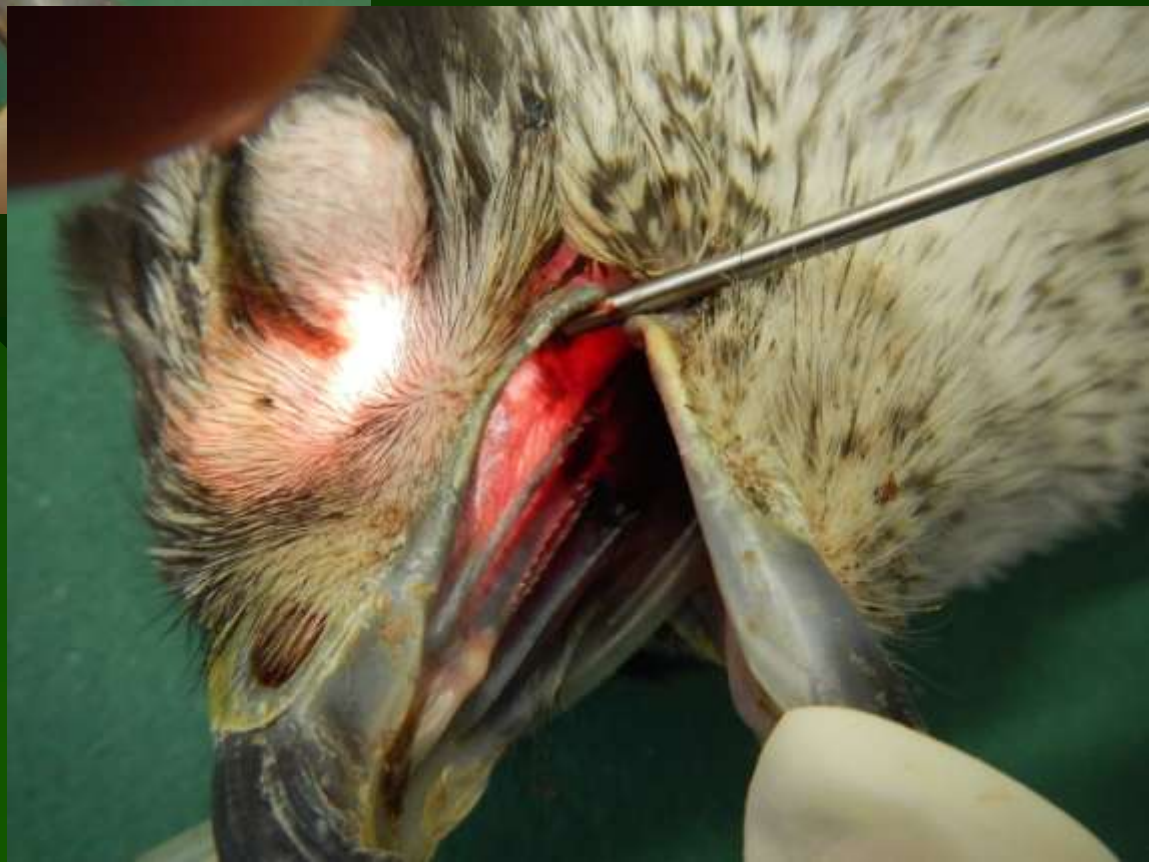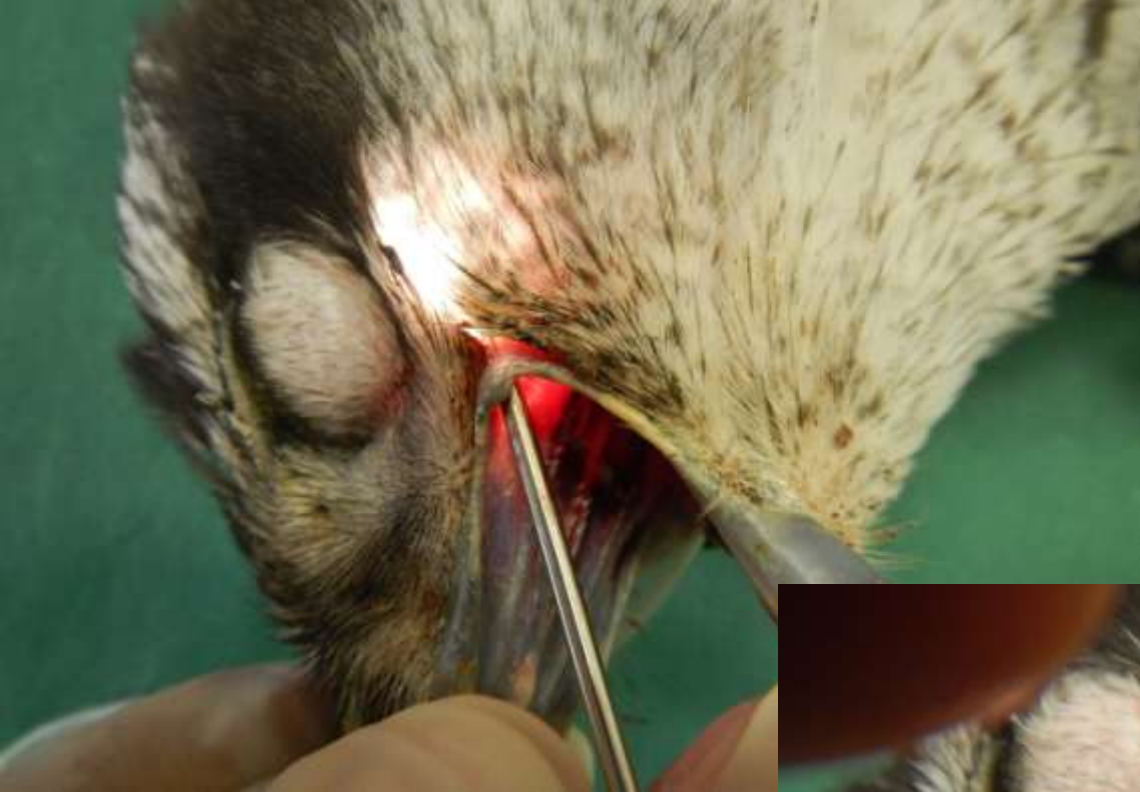Anatomy of choanal structures



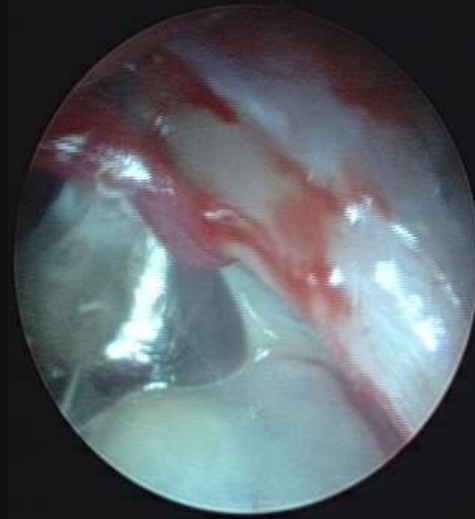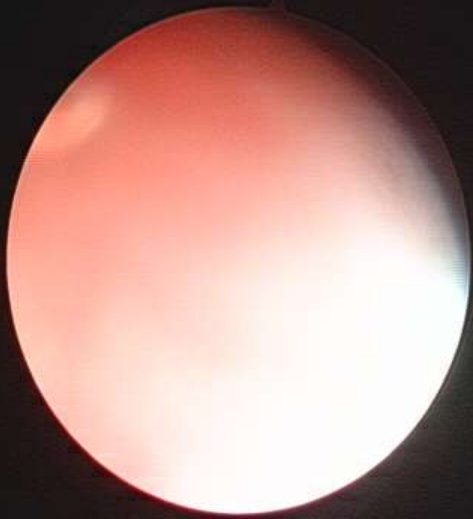Trans-rostral sinus endoscopy

-TRSE

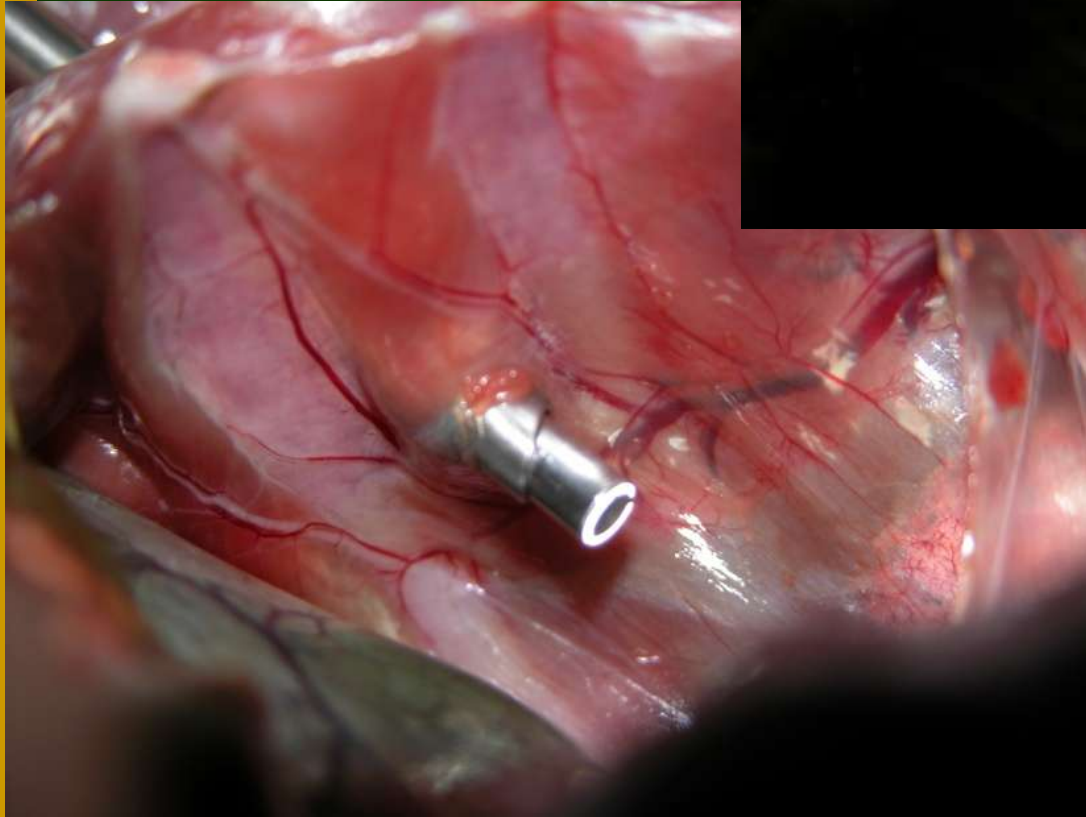
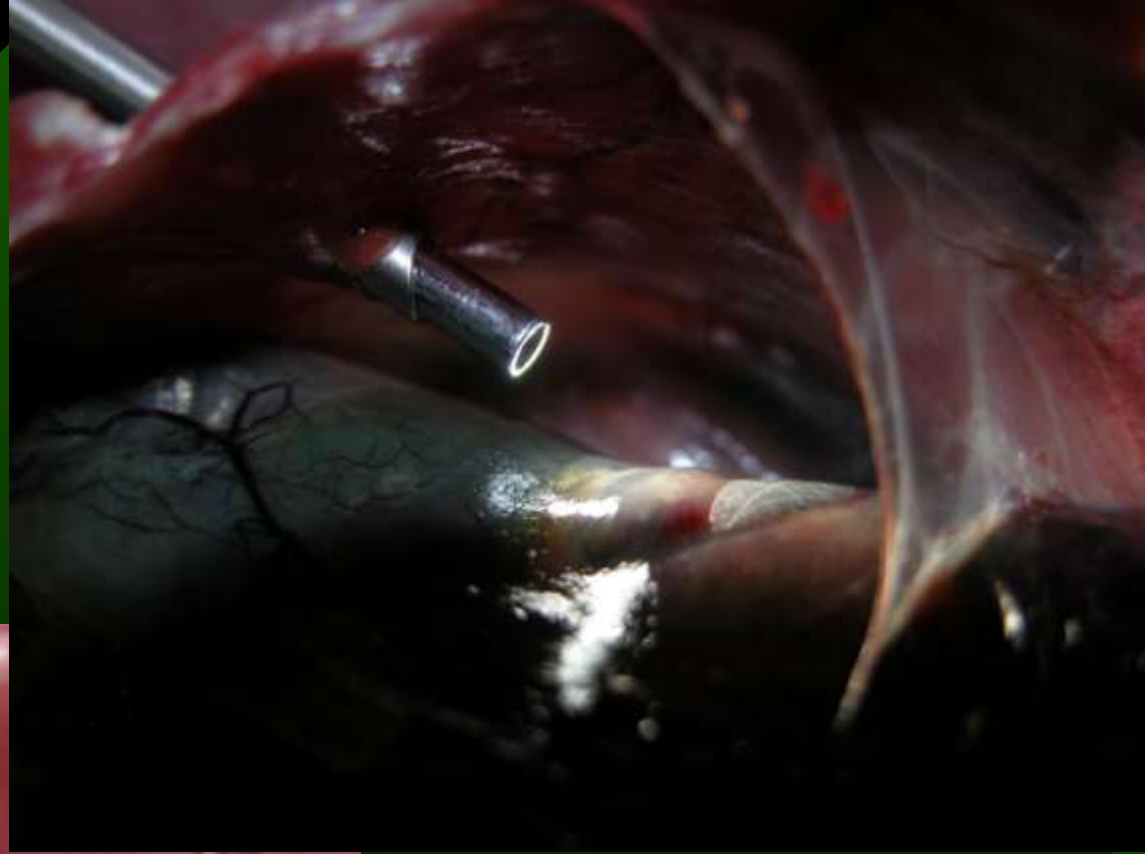



Nasal and retrobulbar sinus endoscopy

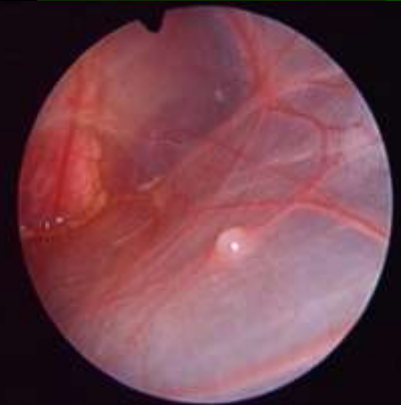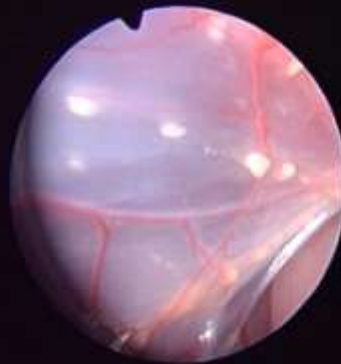
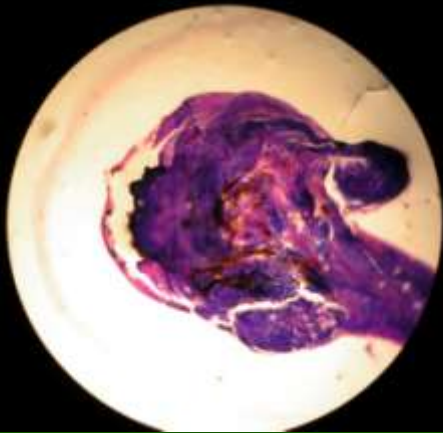
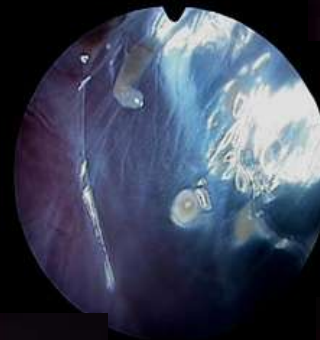
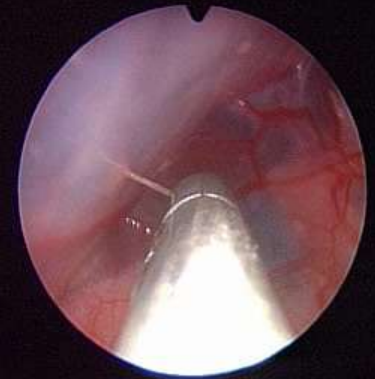
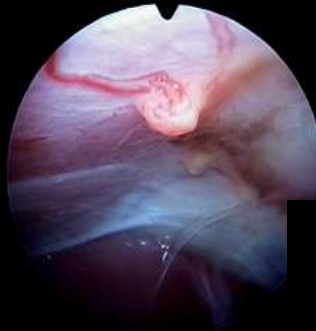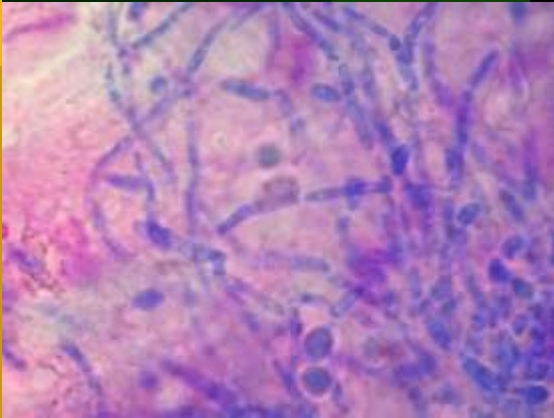


Aspergilosis

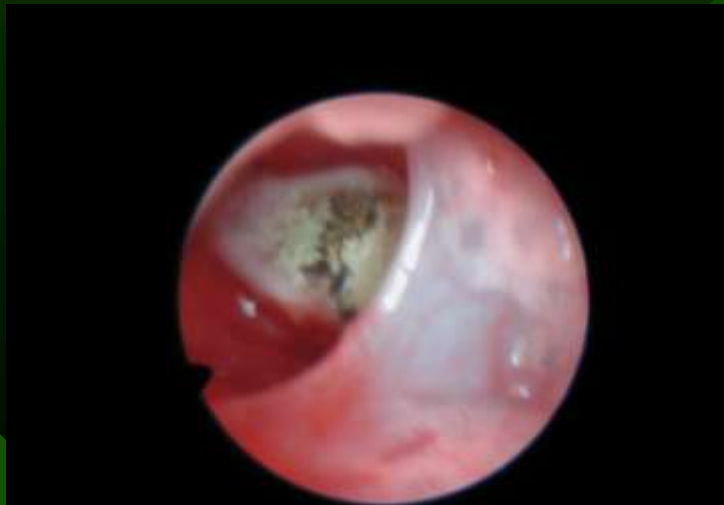
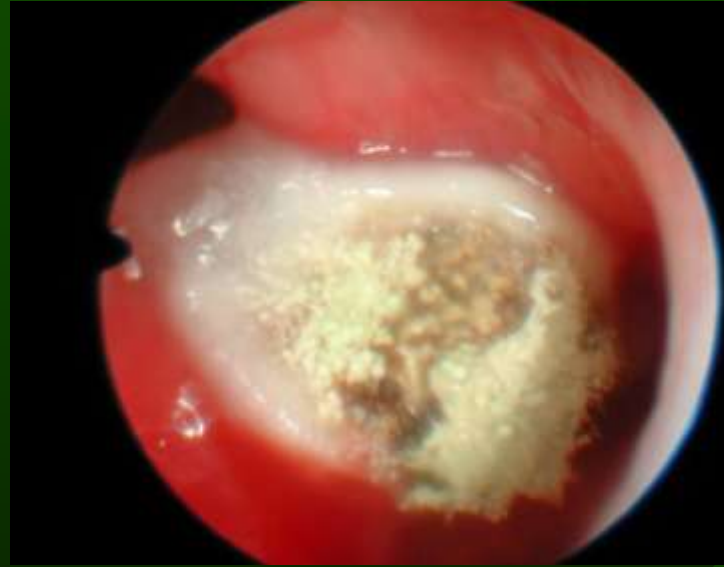
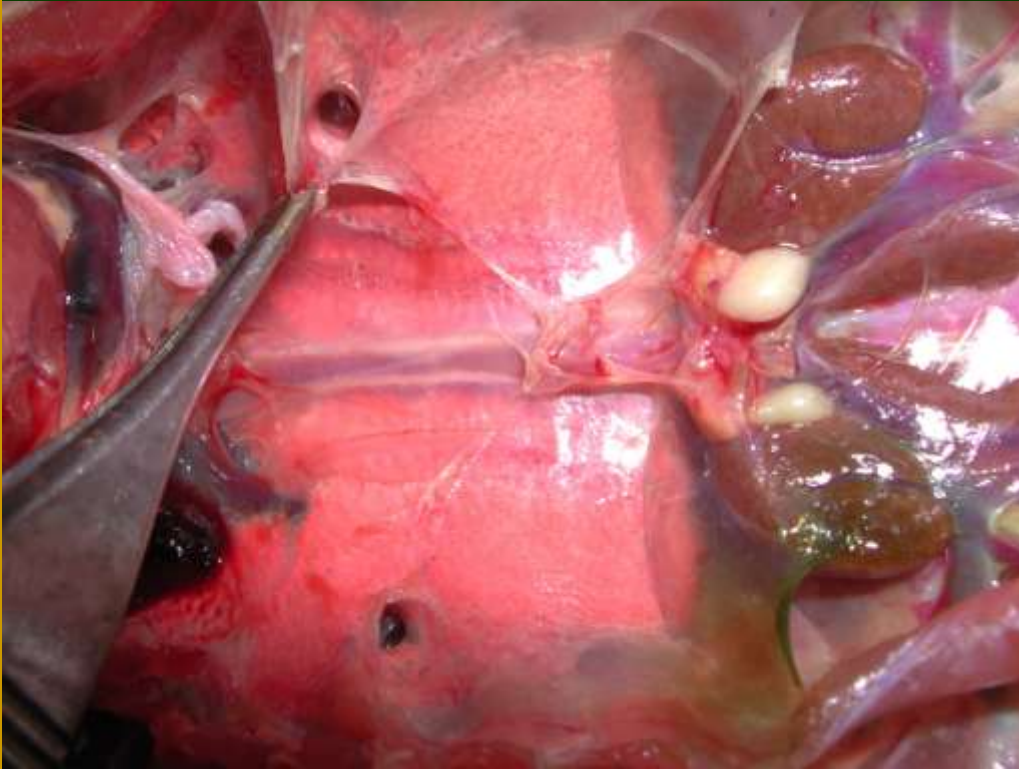Respiratory System-Air Sacs

-early aspergillosis lesions

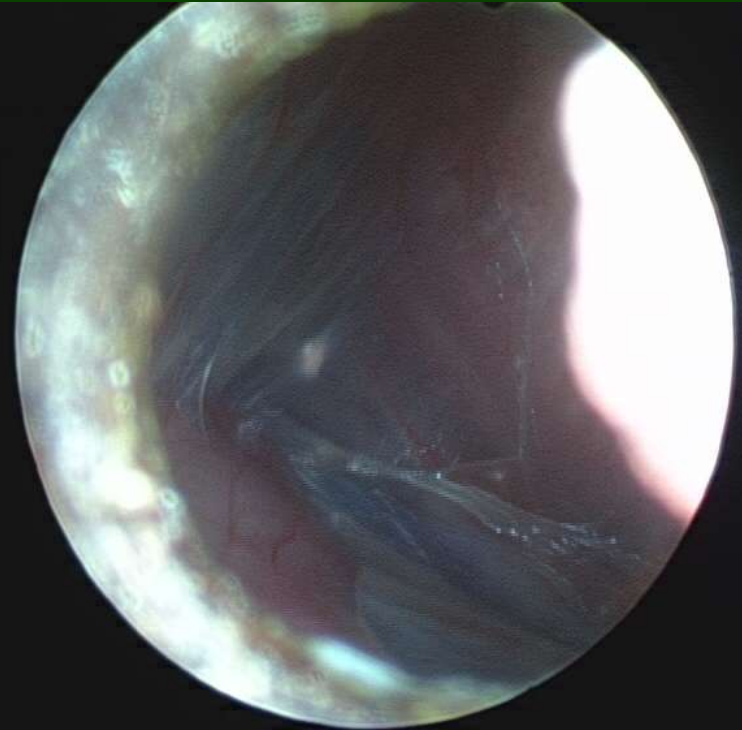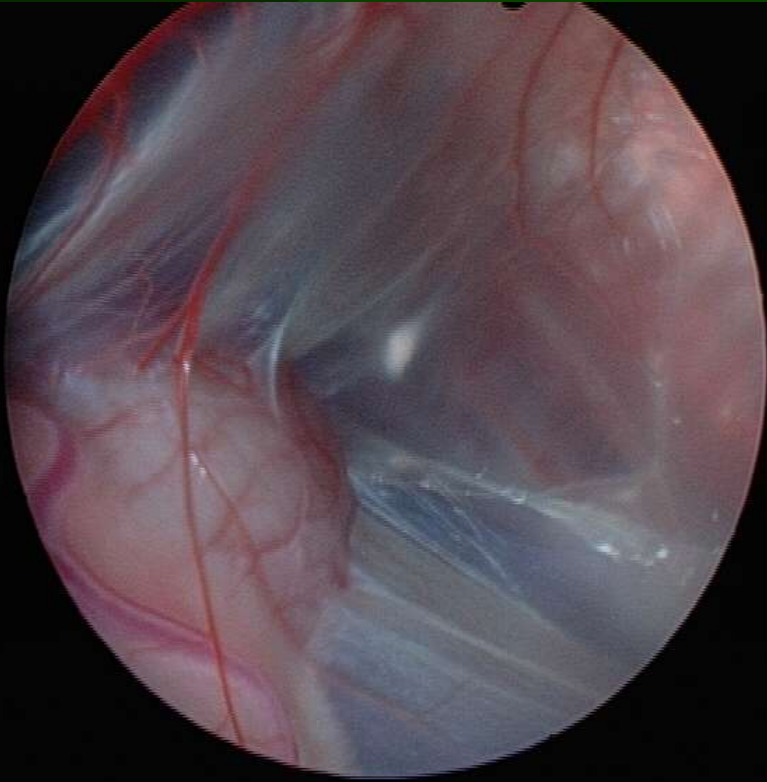


Blocked ostia of ventrobronchy

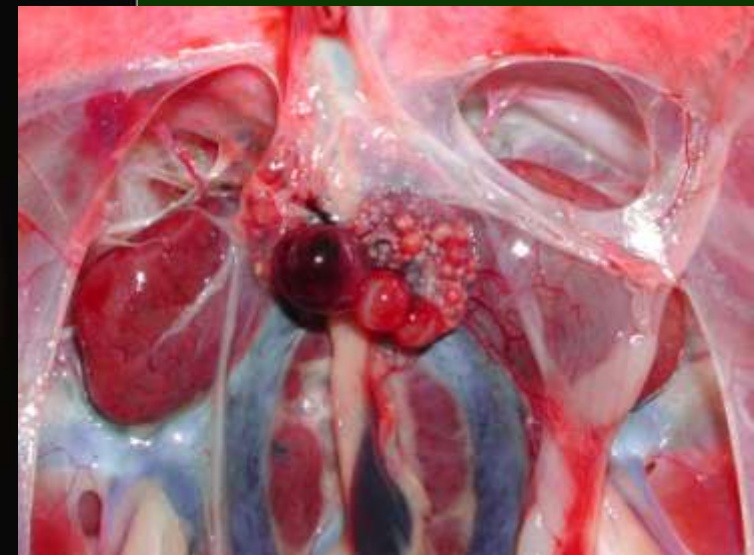
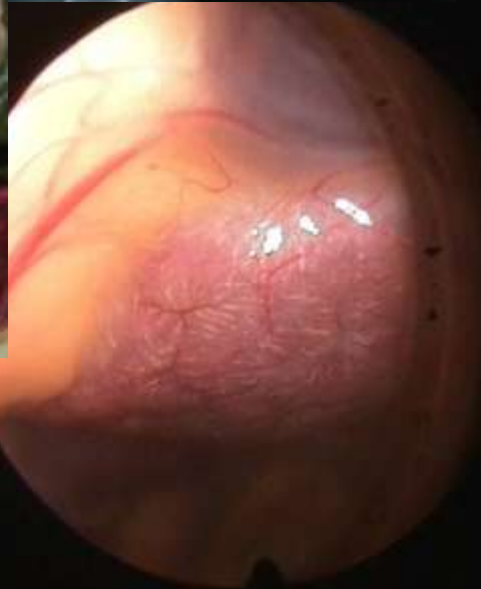
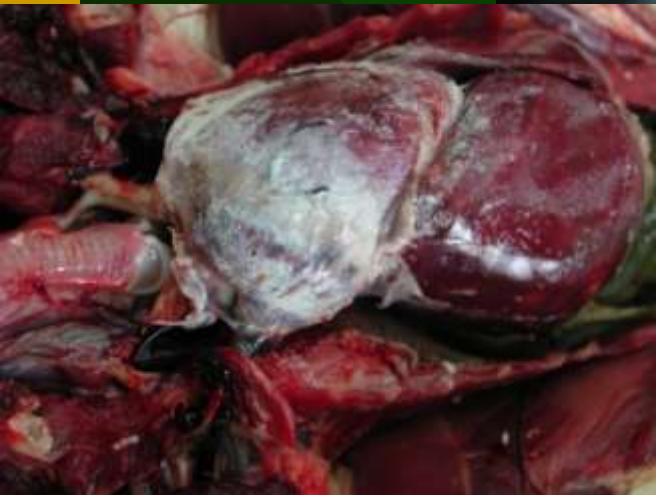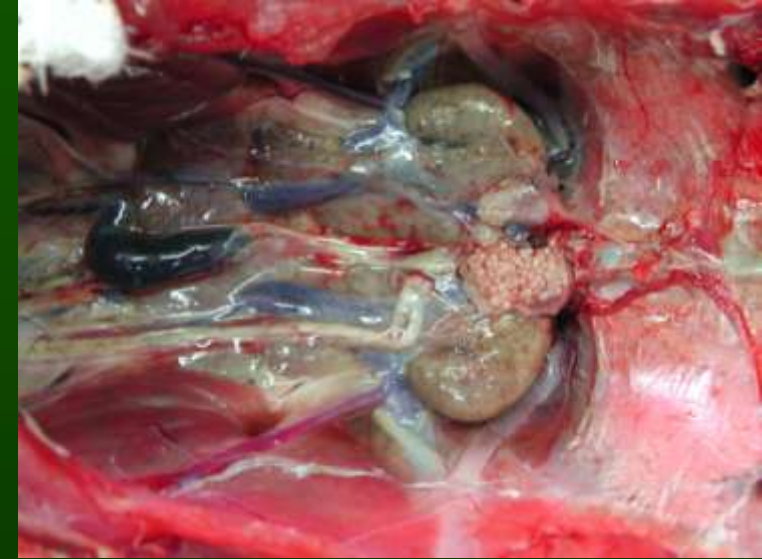
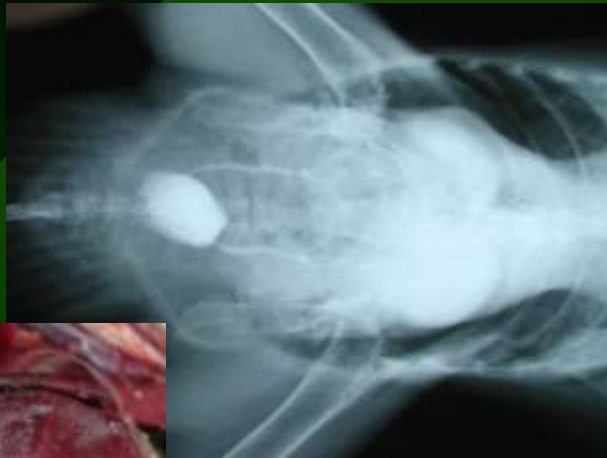


Retro pulmonary tracheoscopy

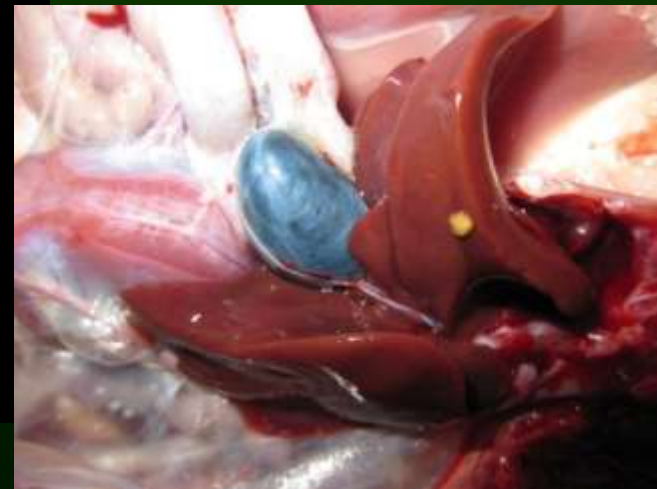
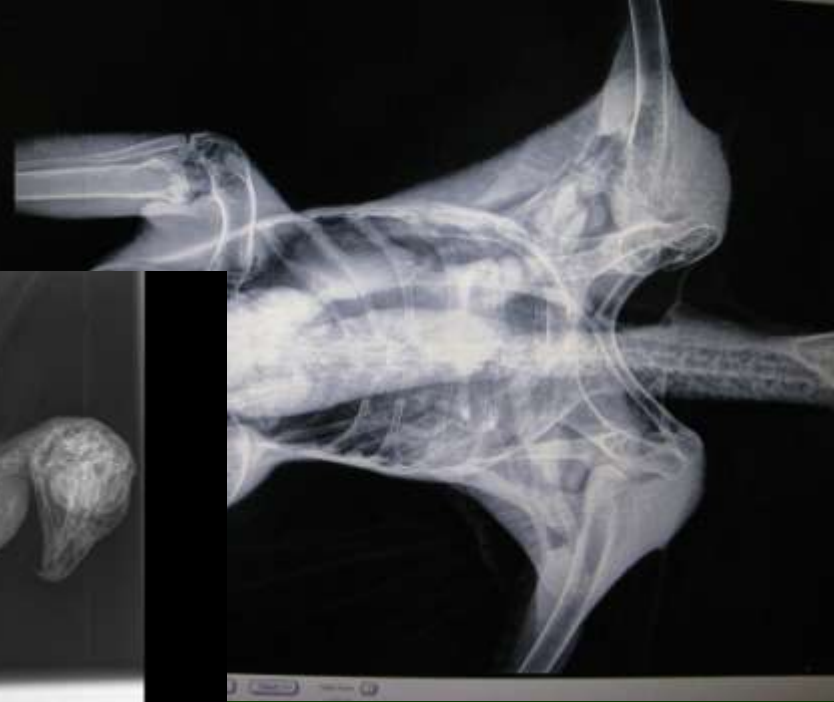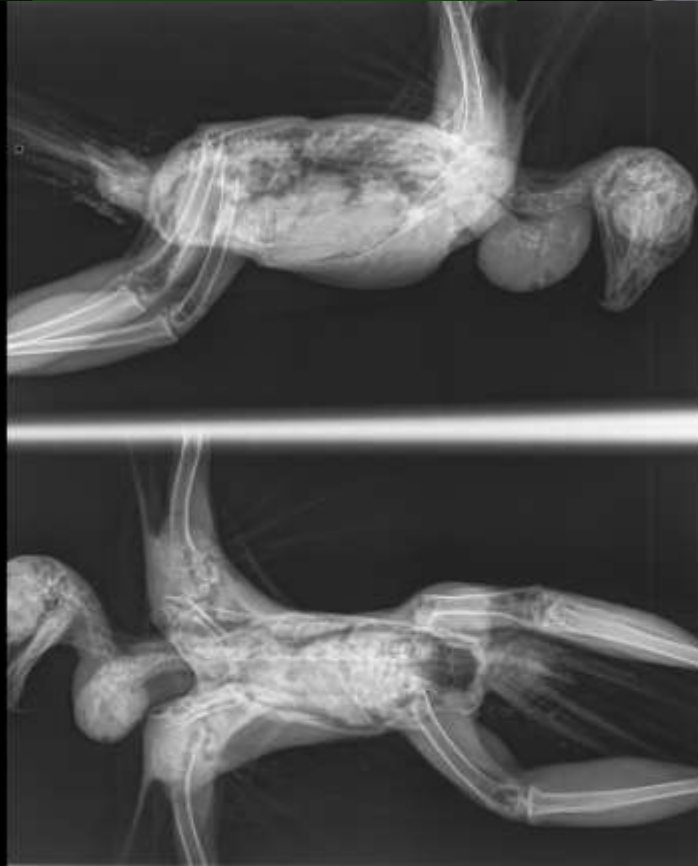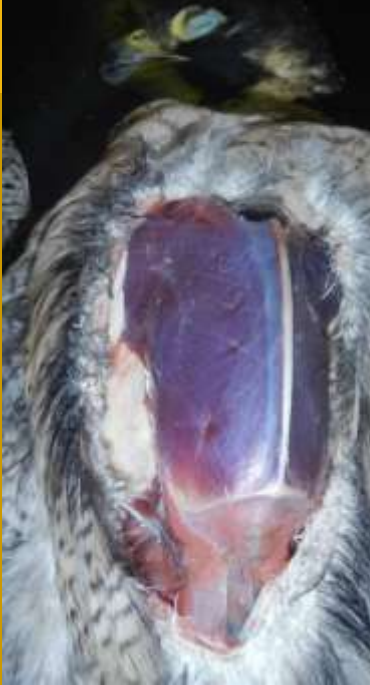Clavicular air sac scoping



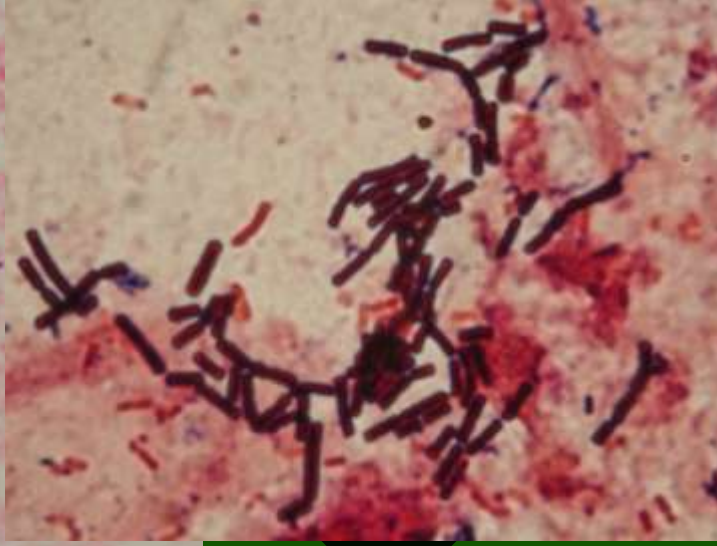
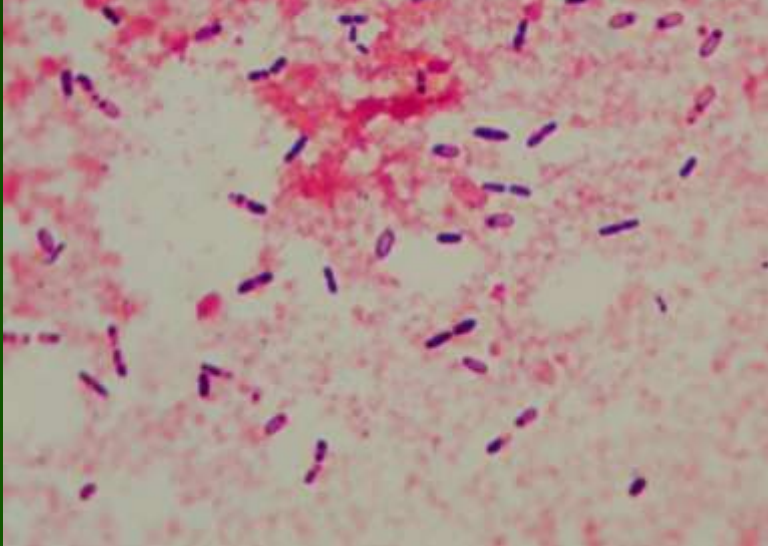
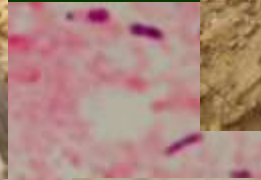
Urate gout



Sour crop



Food poisoning



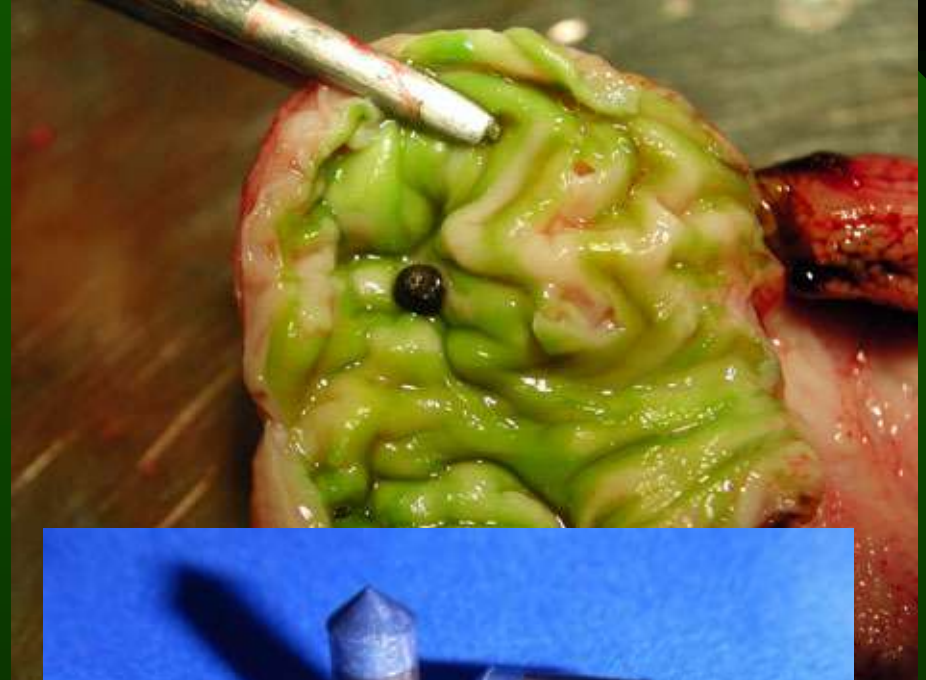[REDACTED]

[REDACTED]

[REDACTED]

[REDACTED]

Lead poisoning



- 20 % Xray pozitiv
- Blood Pb and ALAD
- Repeated EDTA 40mg/kg treatment



Thank you

